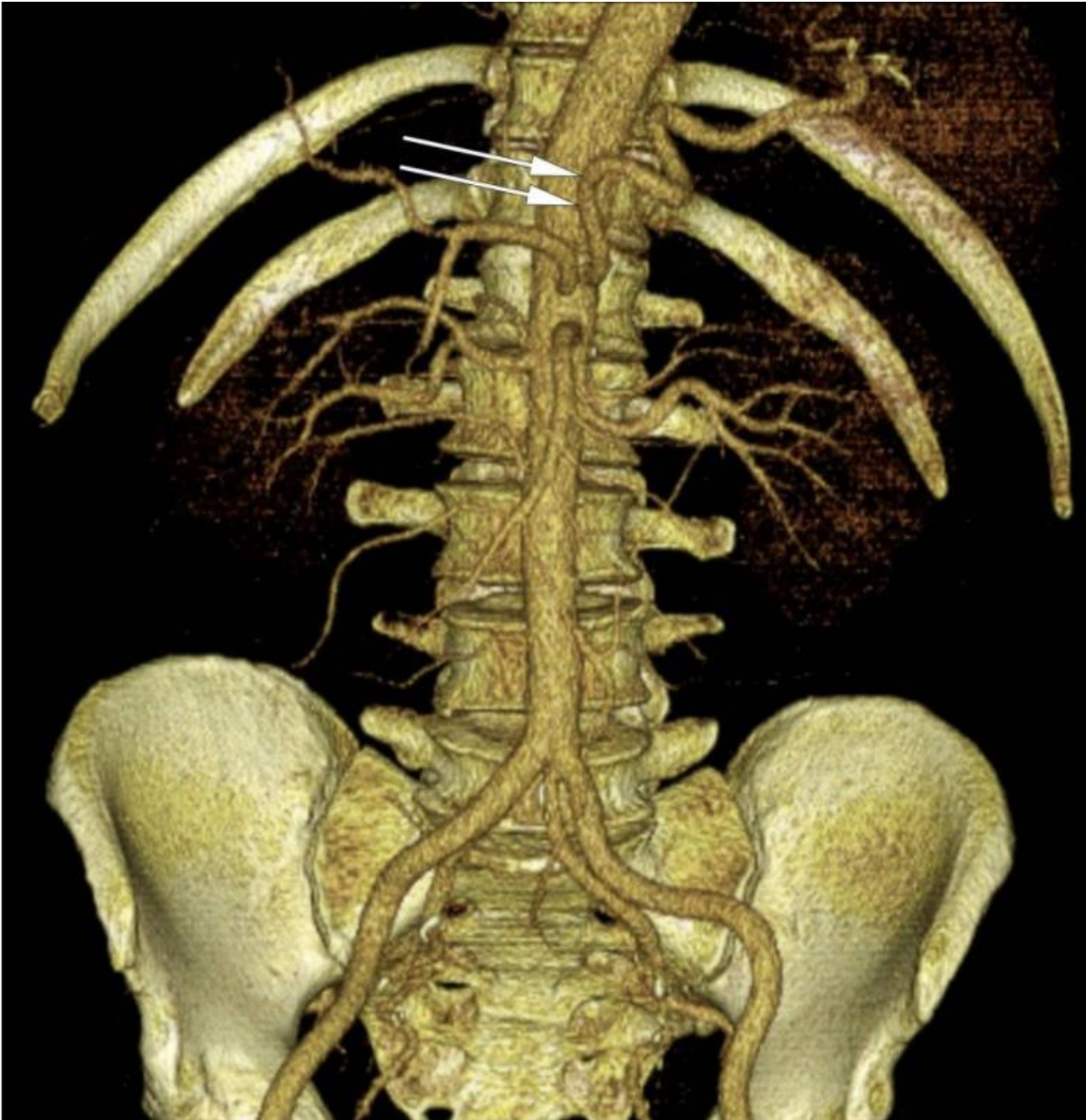


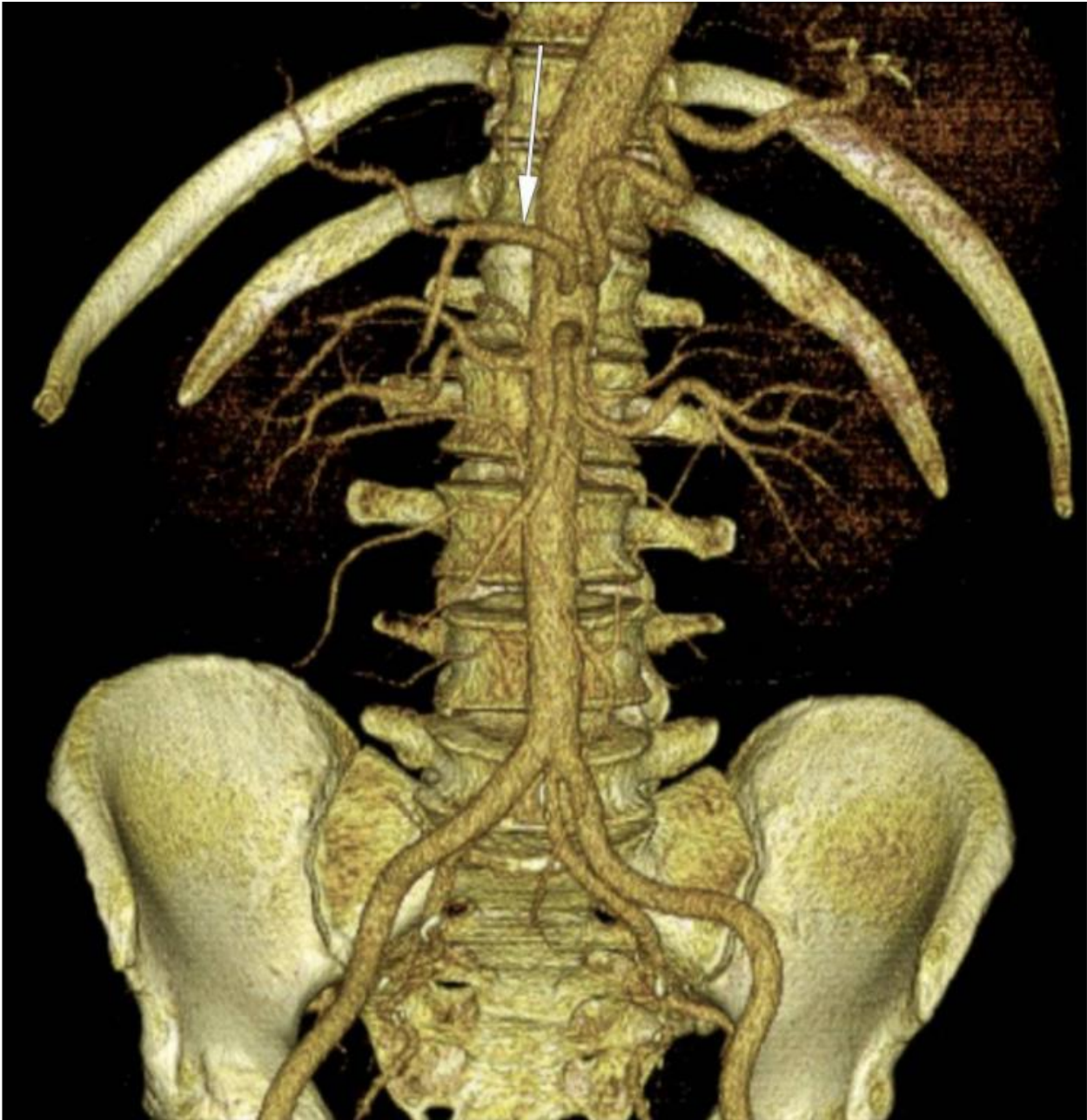
Radiographic anatomy of normal variants

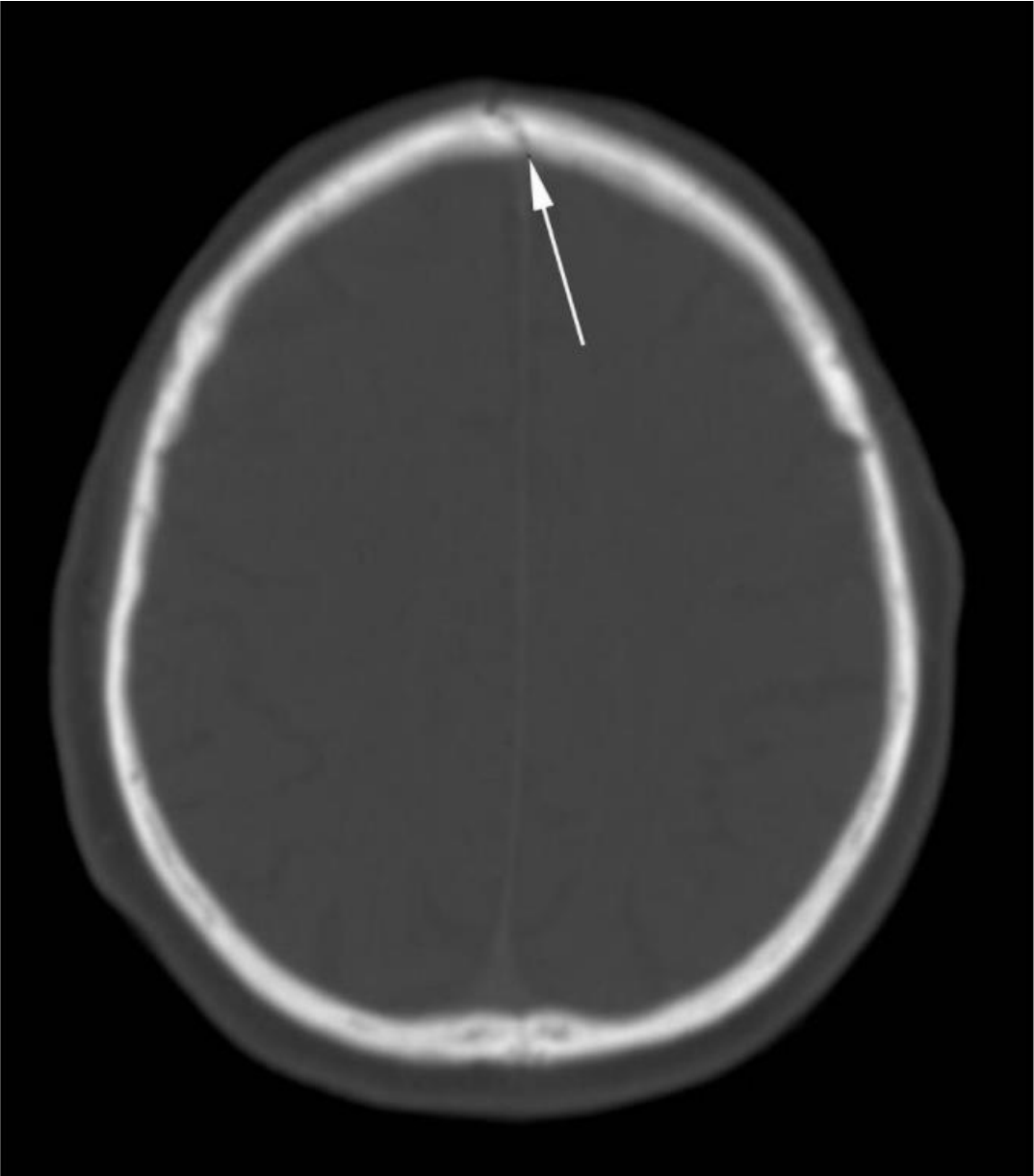
(test bank for FRCR Part 1 exam)

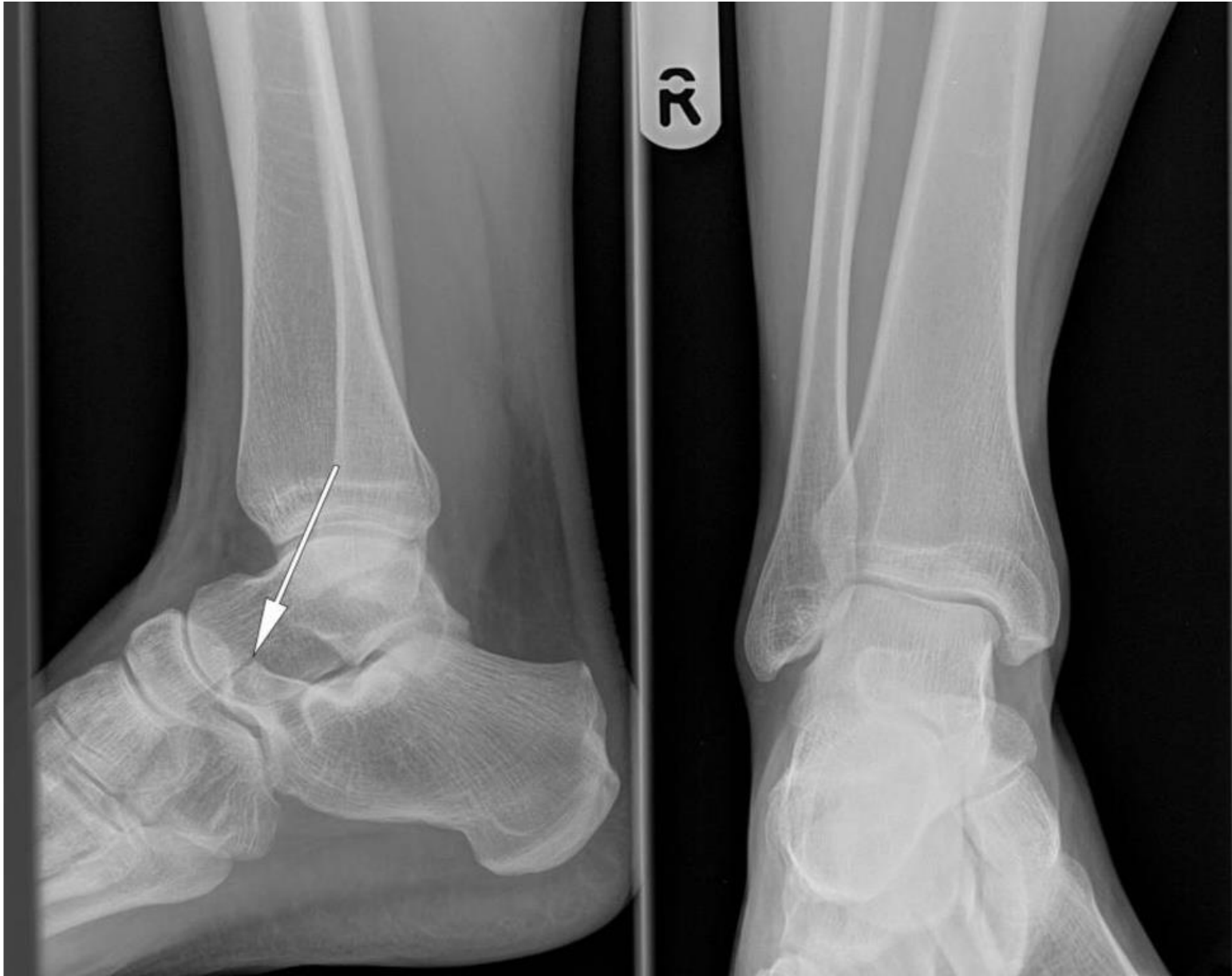Gilbert Gravino
Radiology Registrar

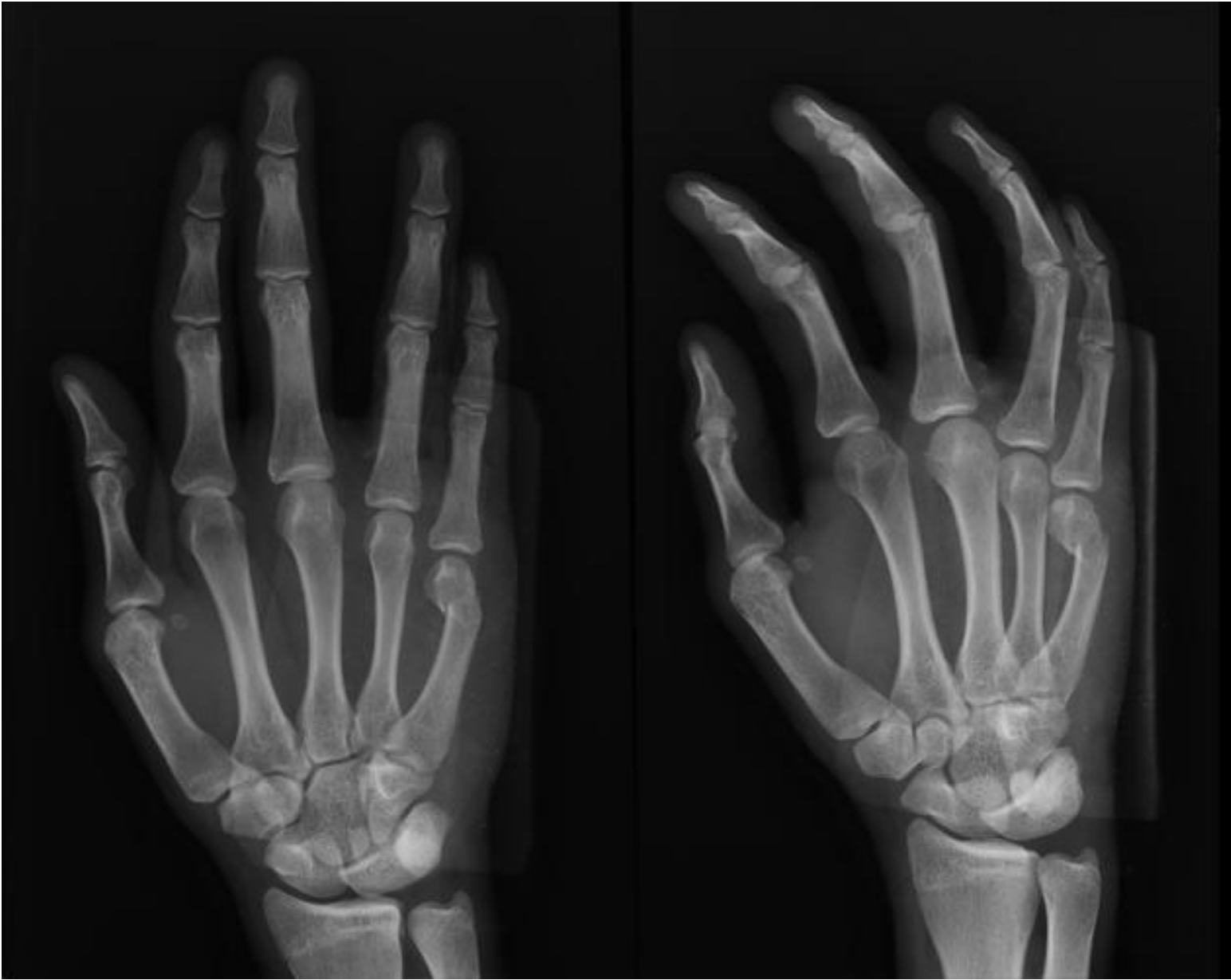2020

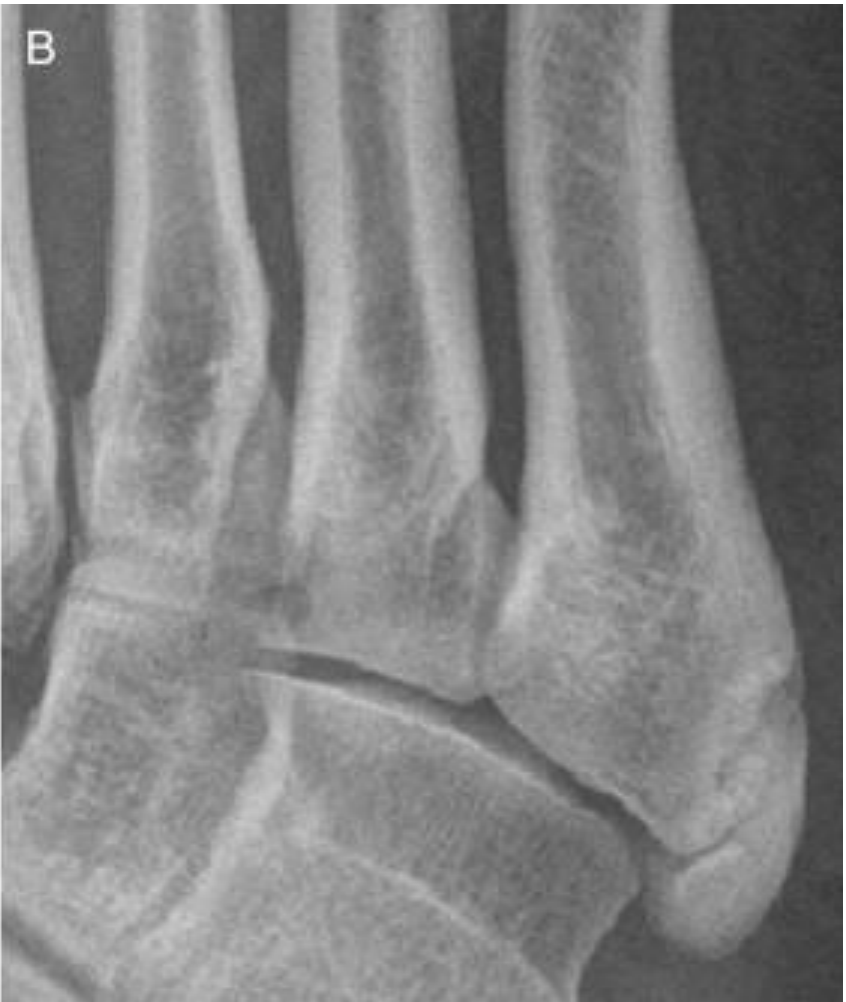
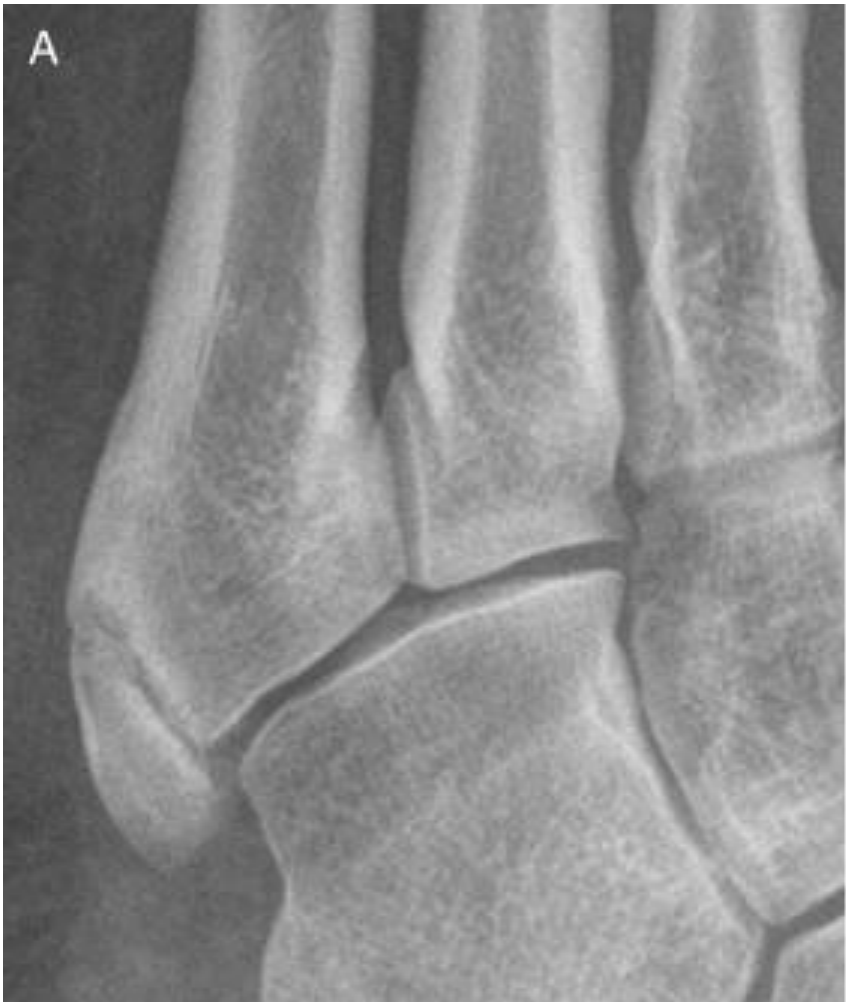
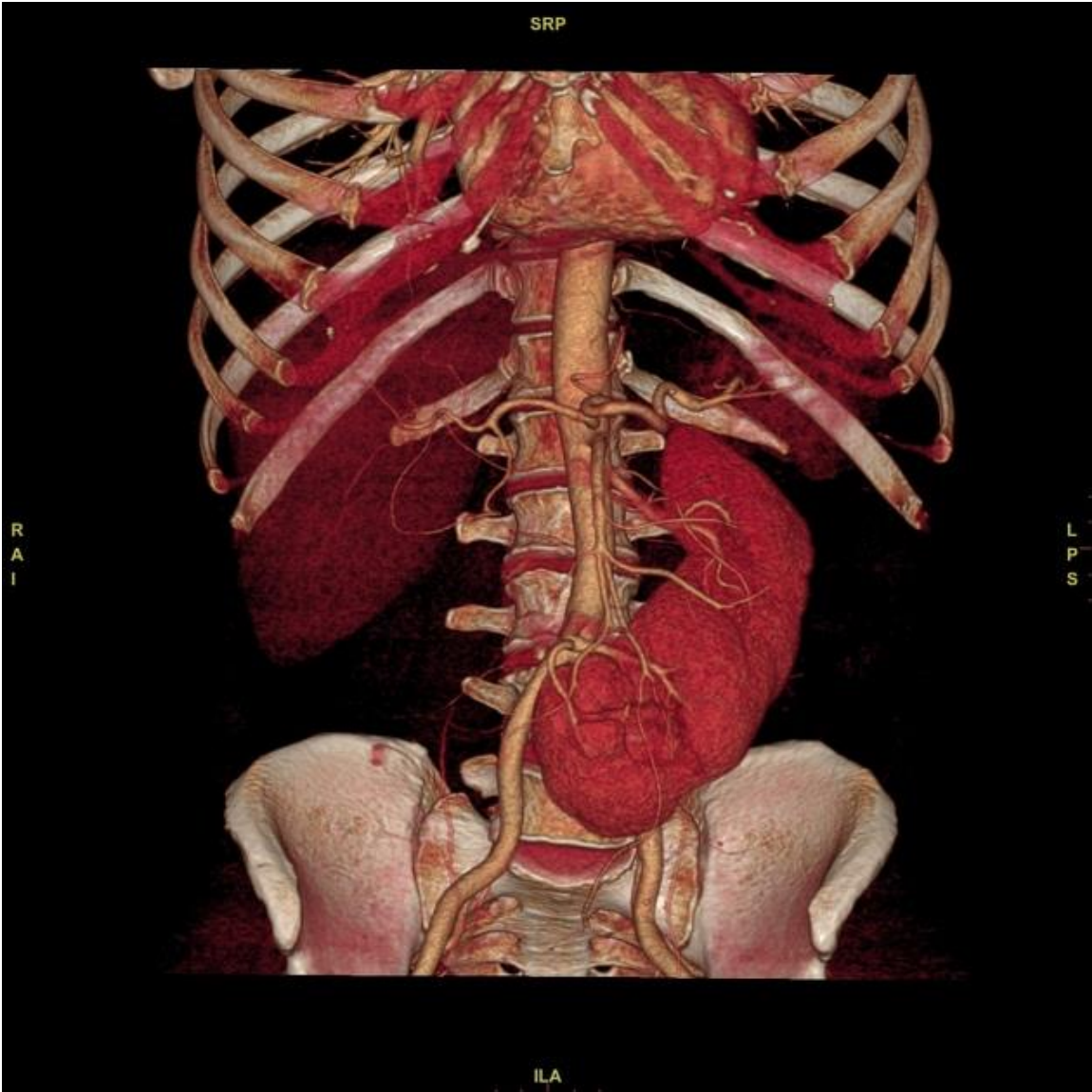


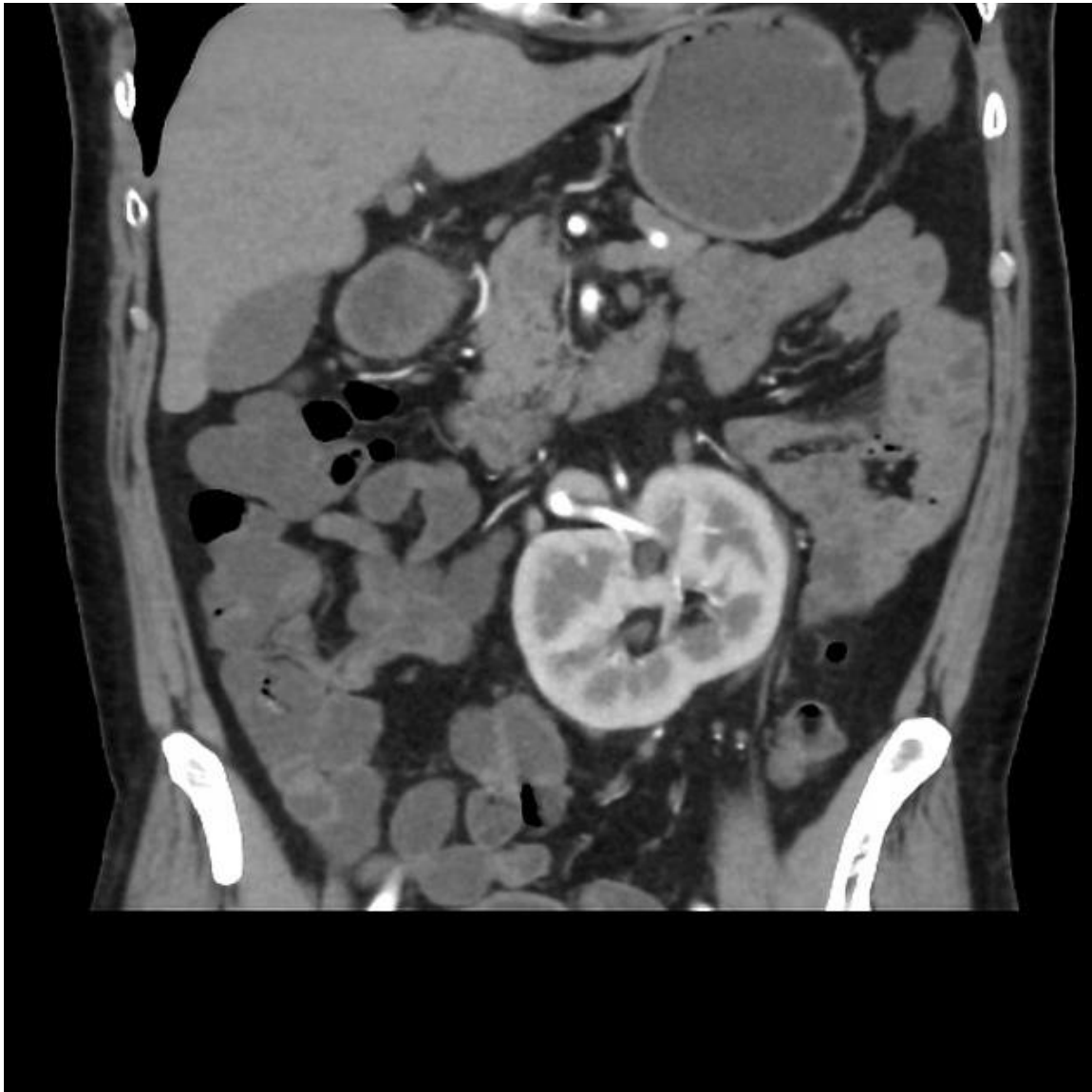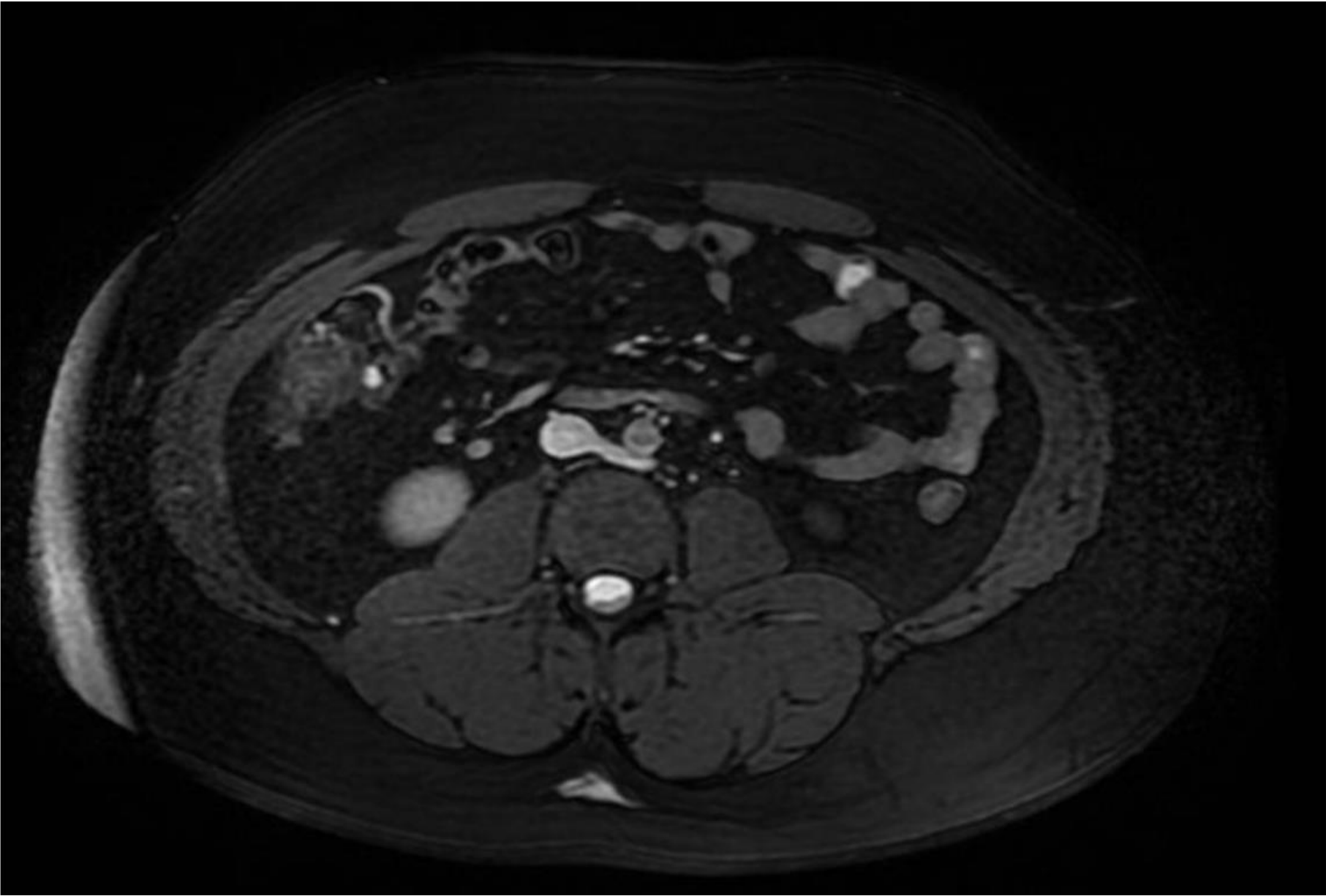





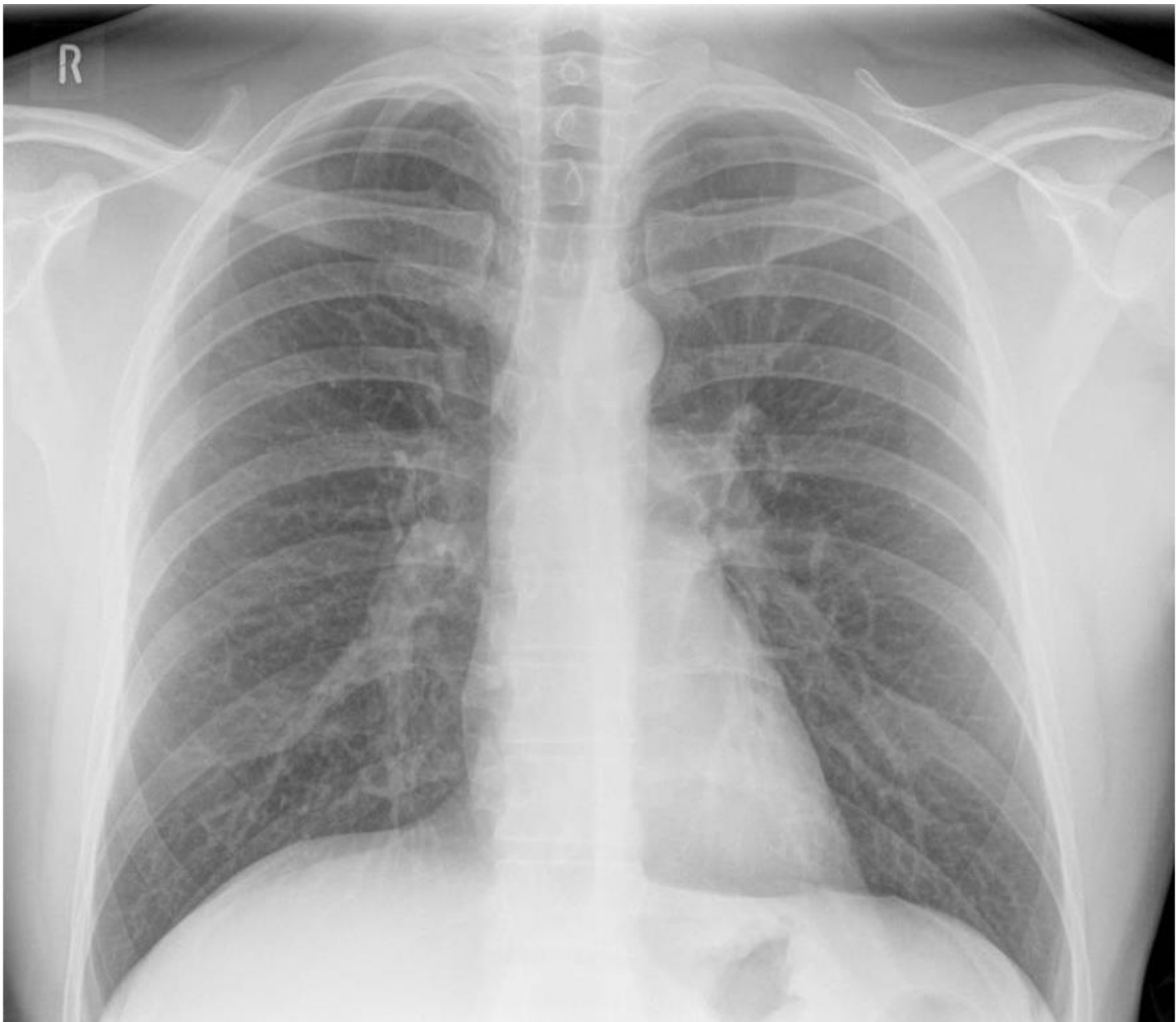
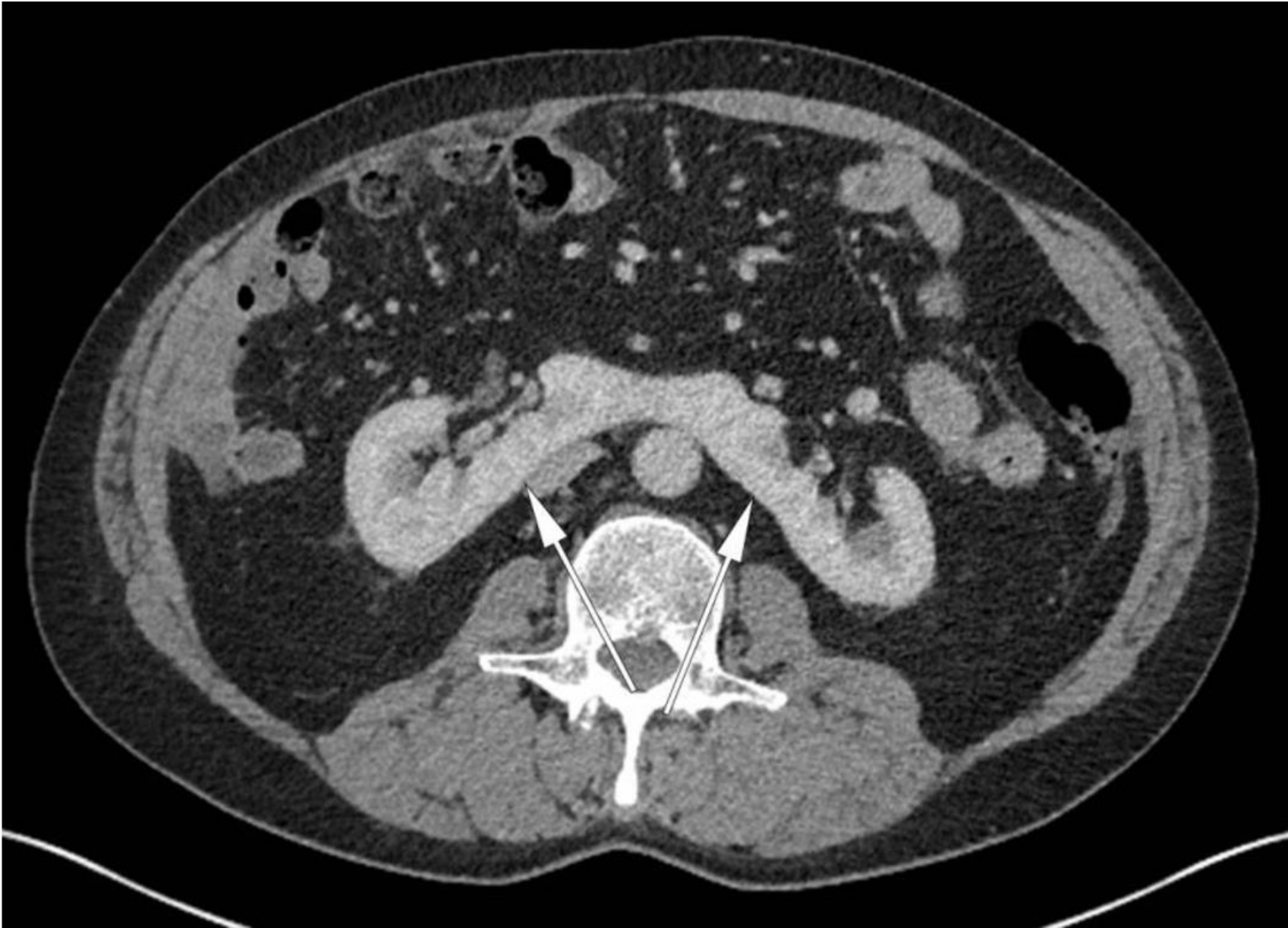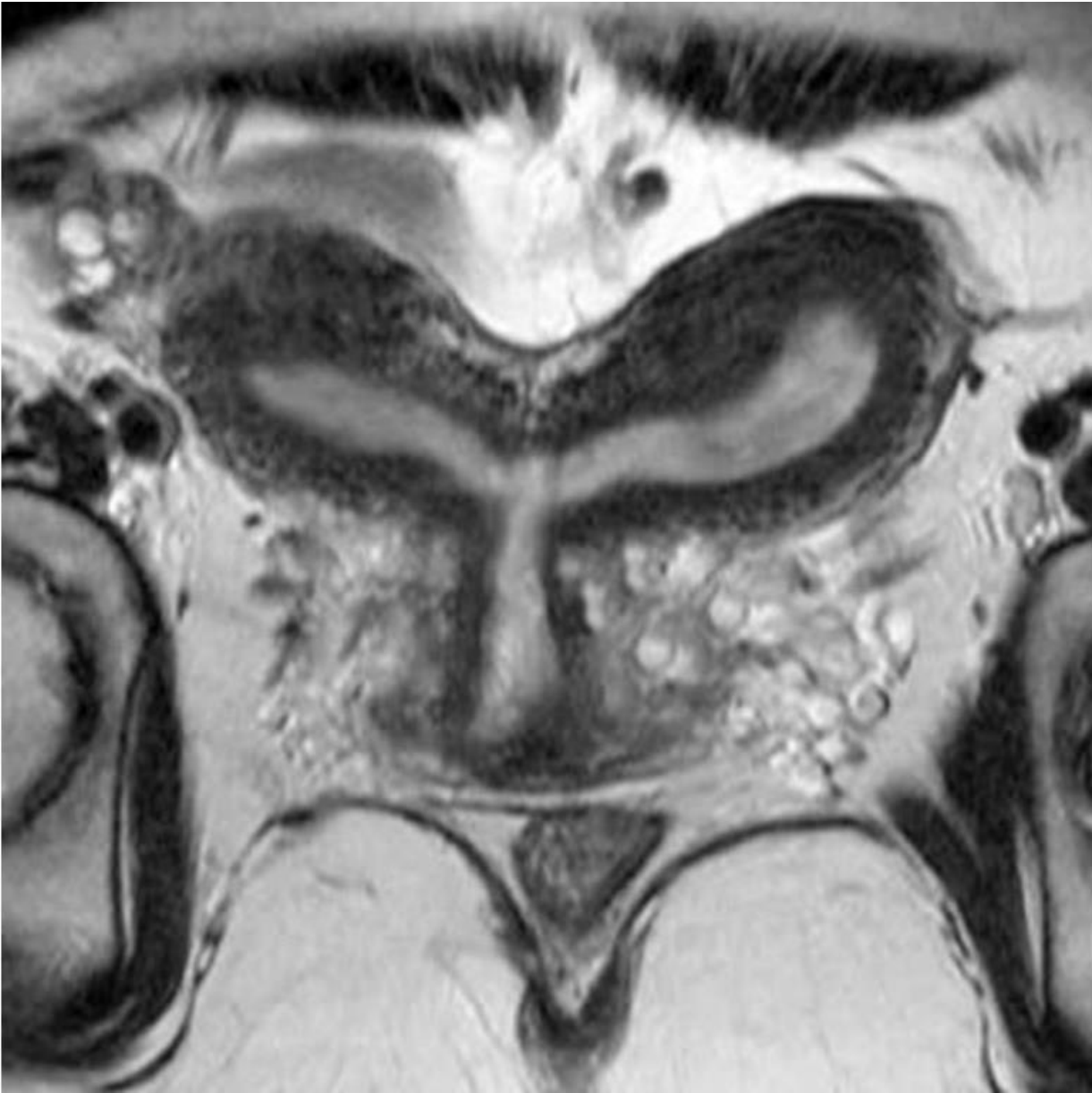


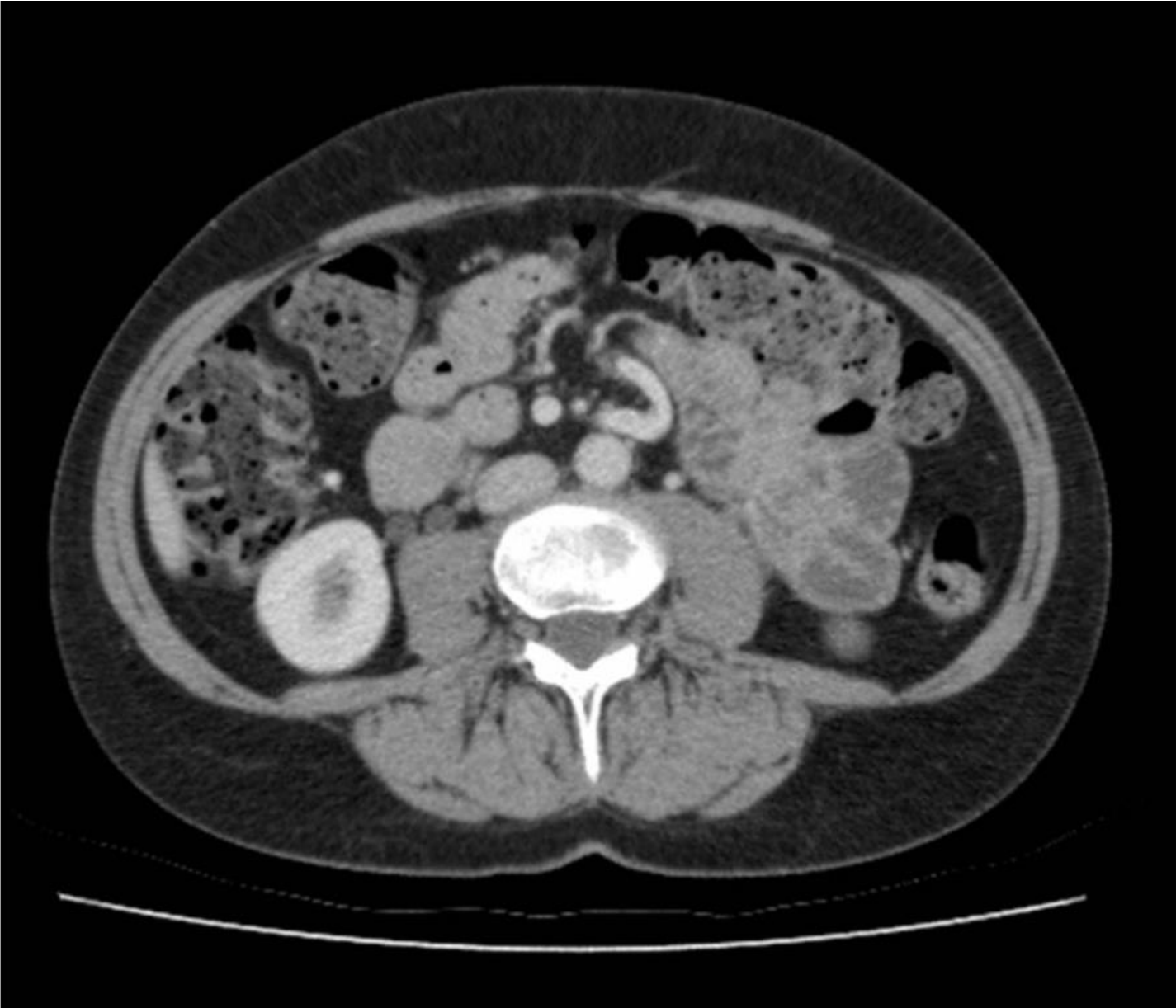







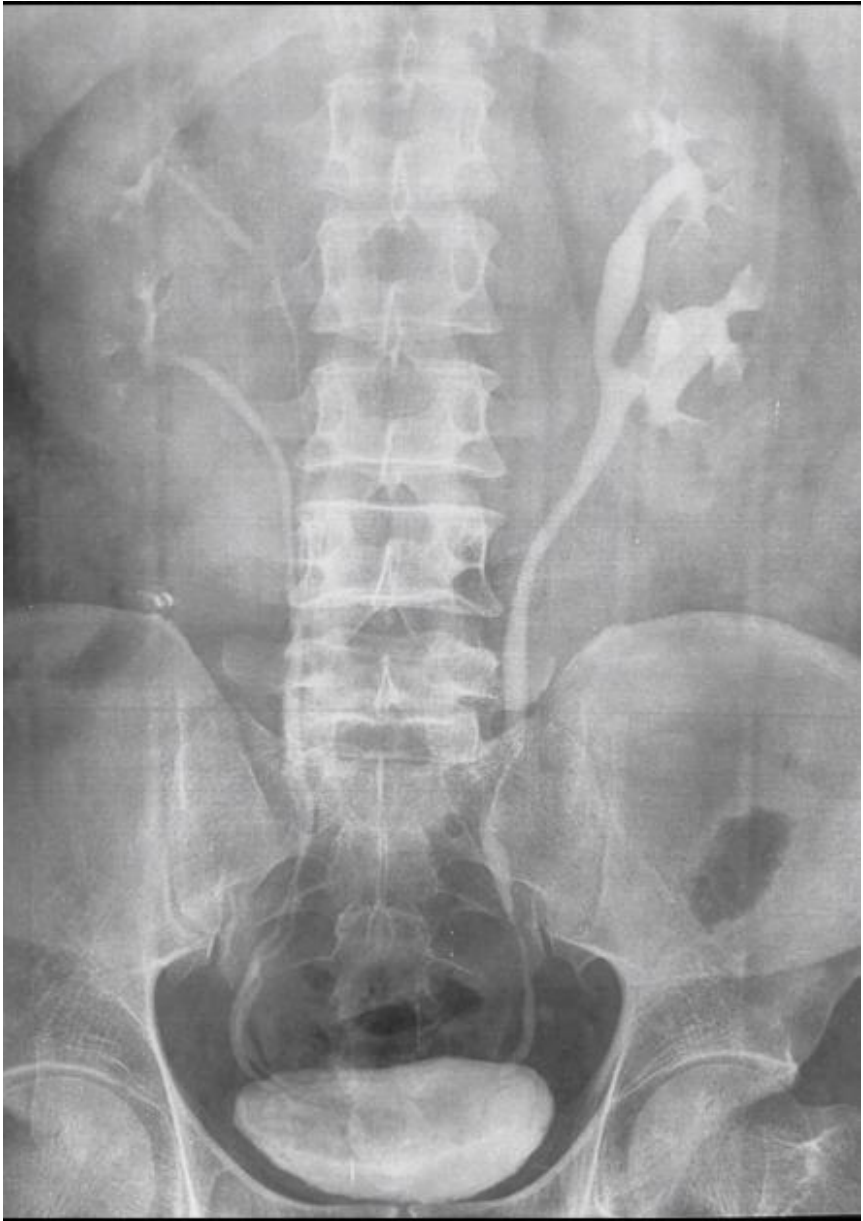
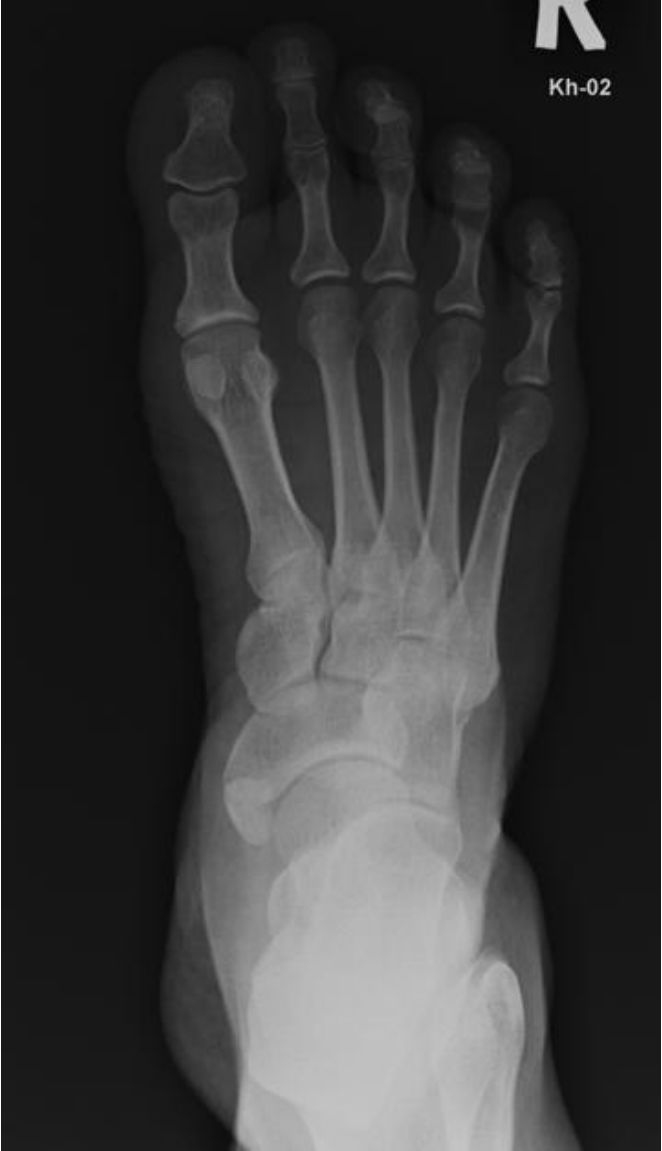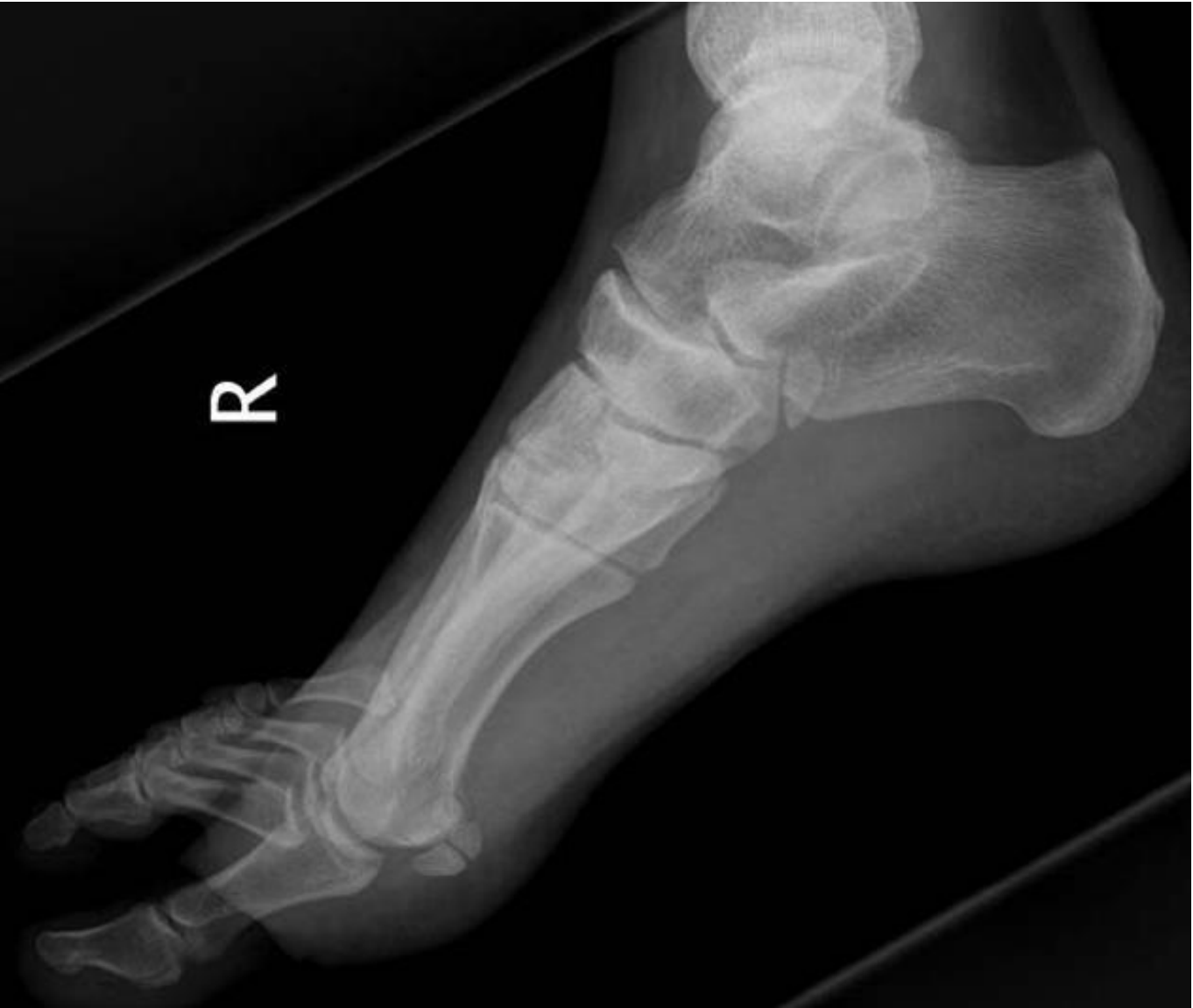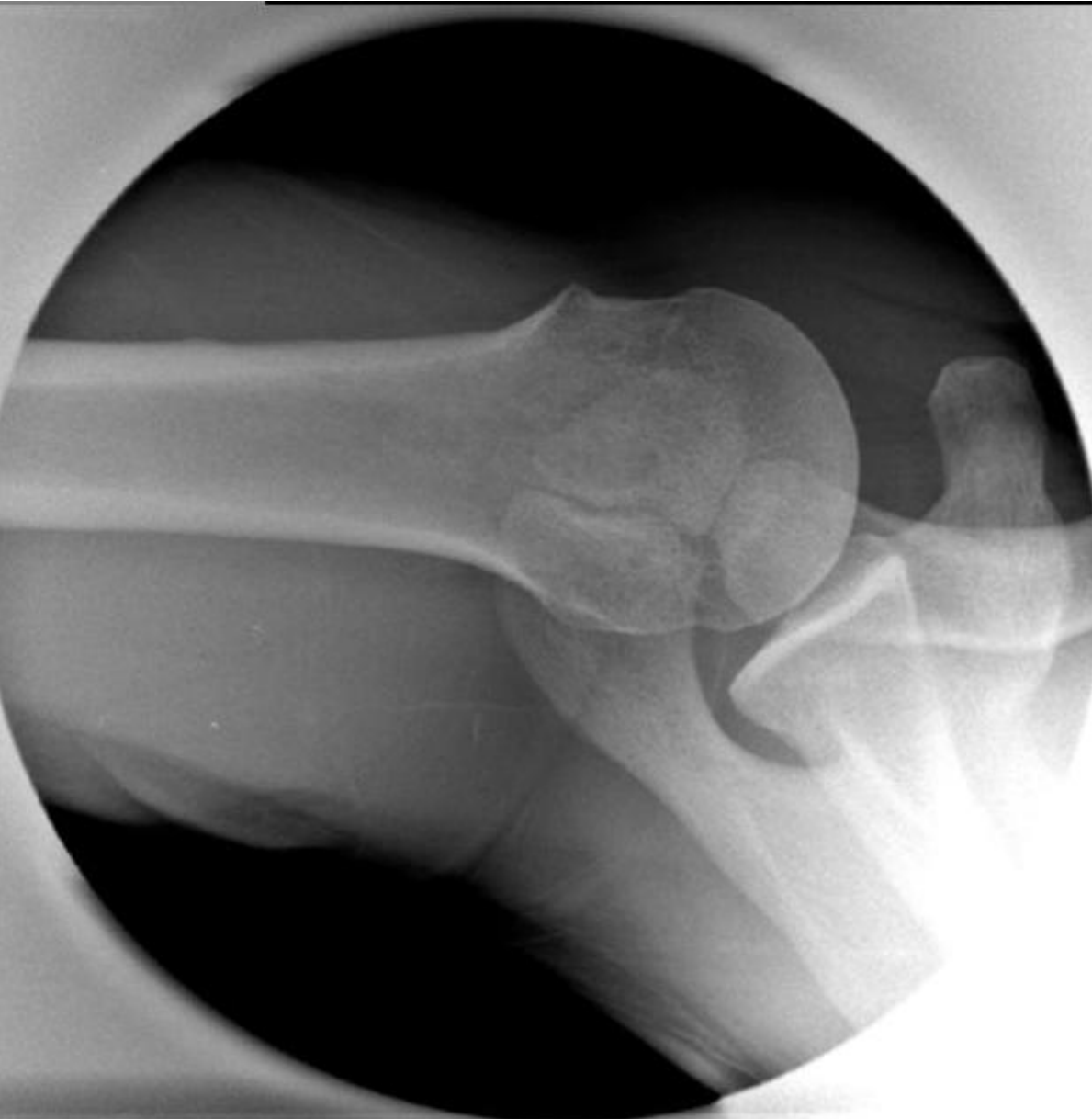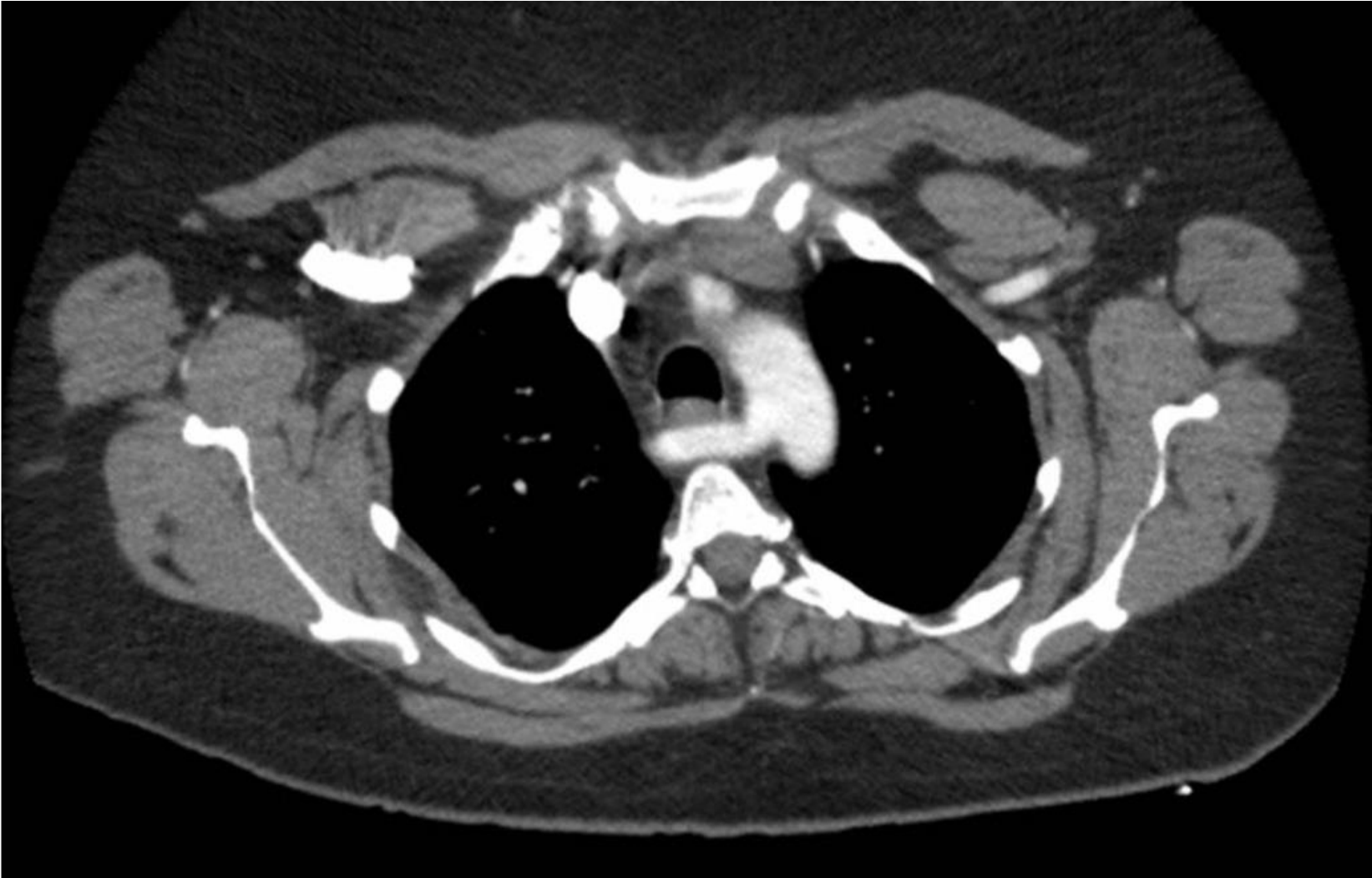


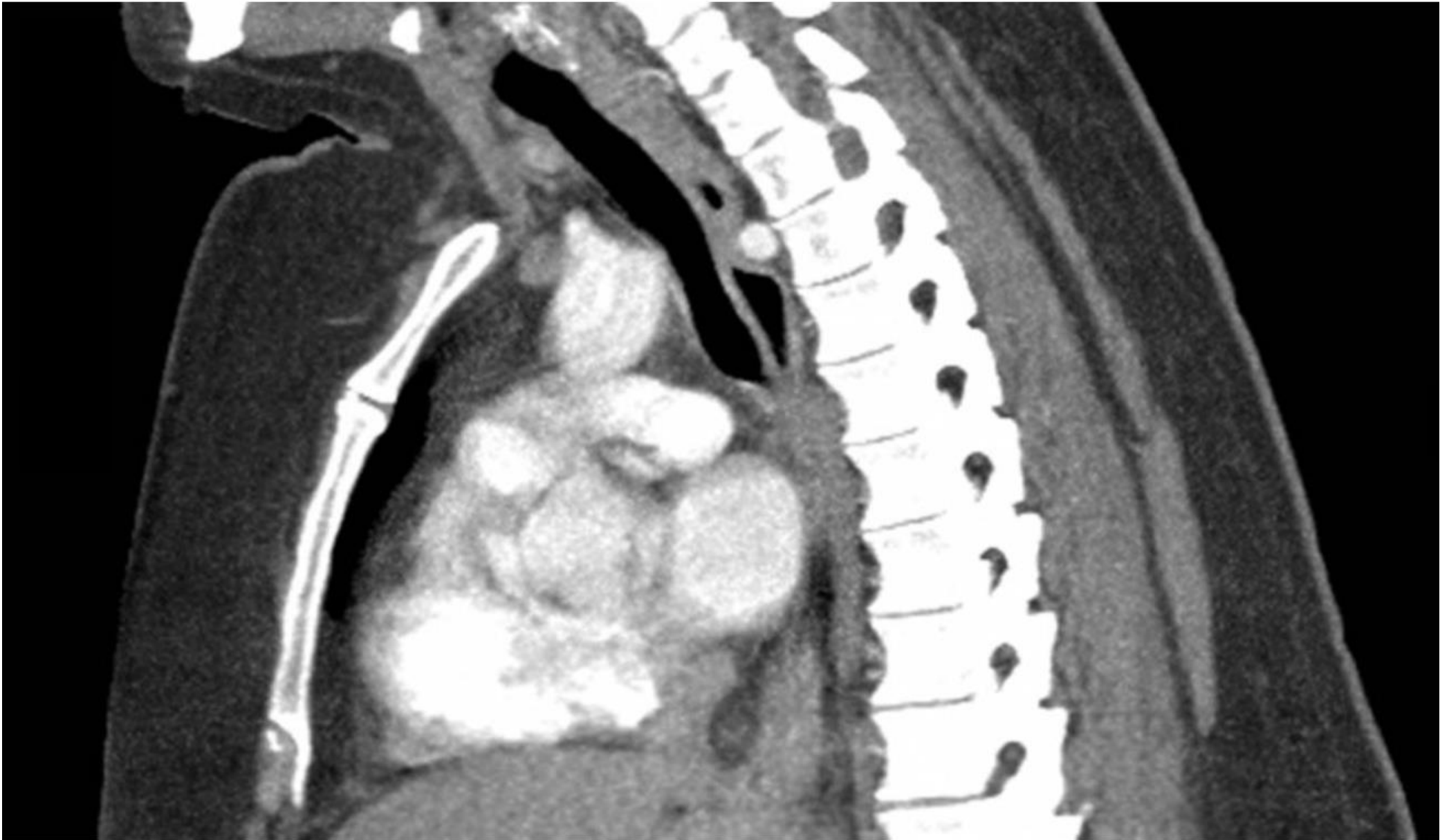




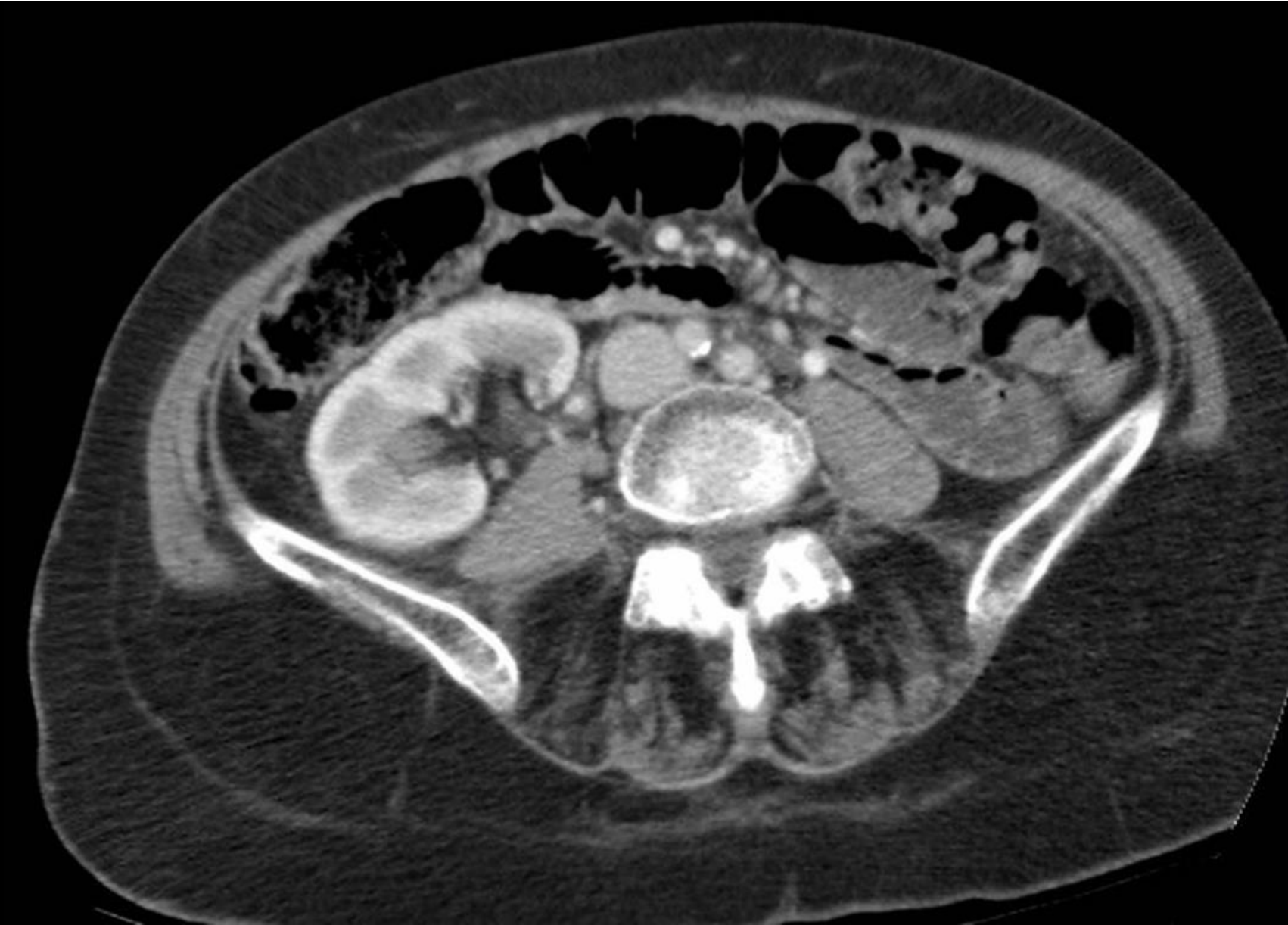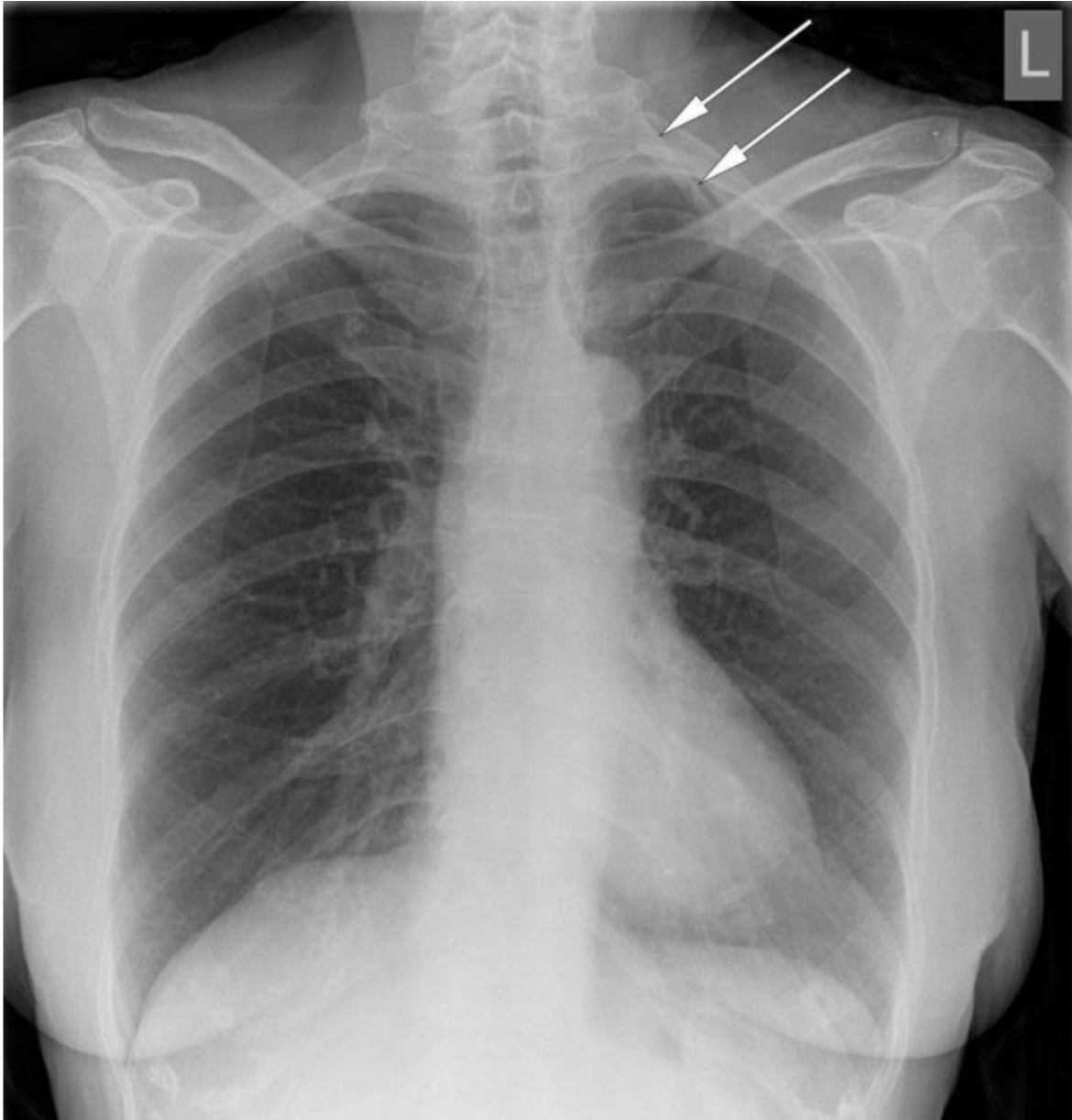










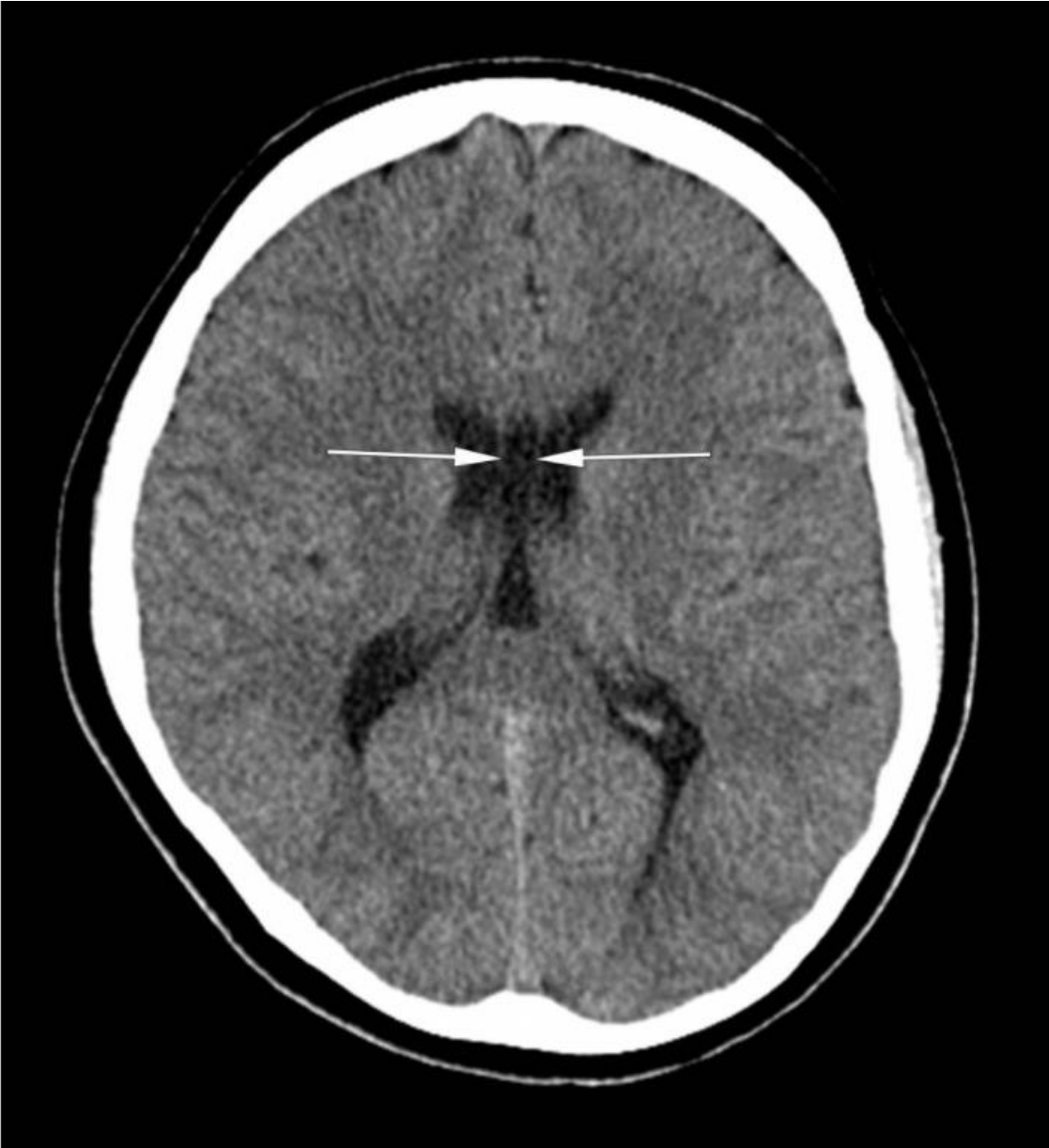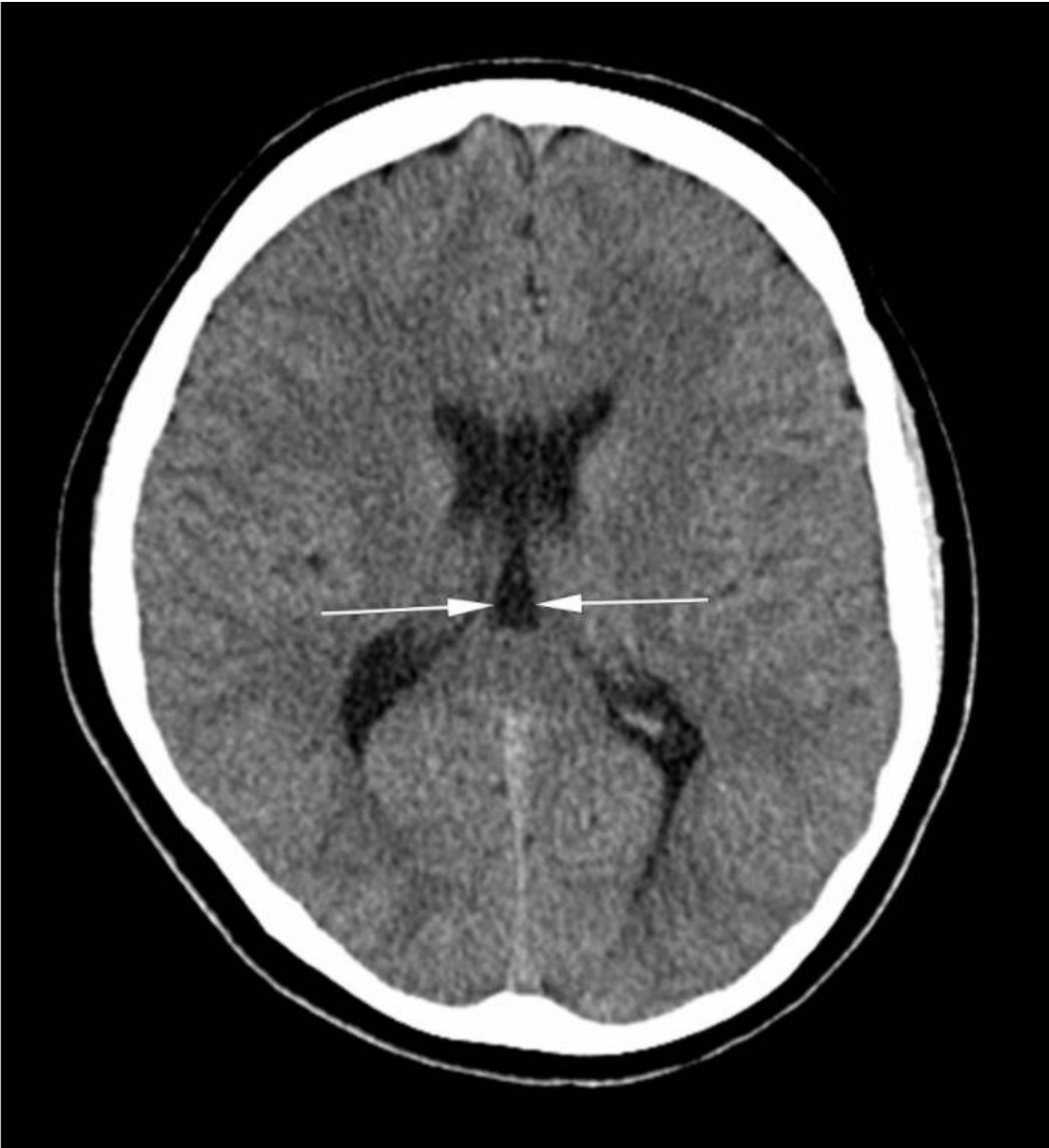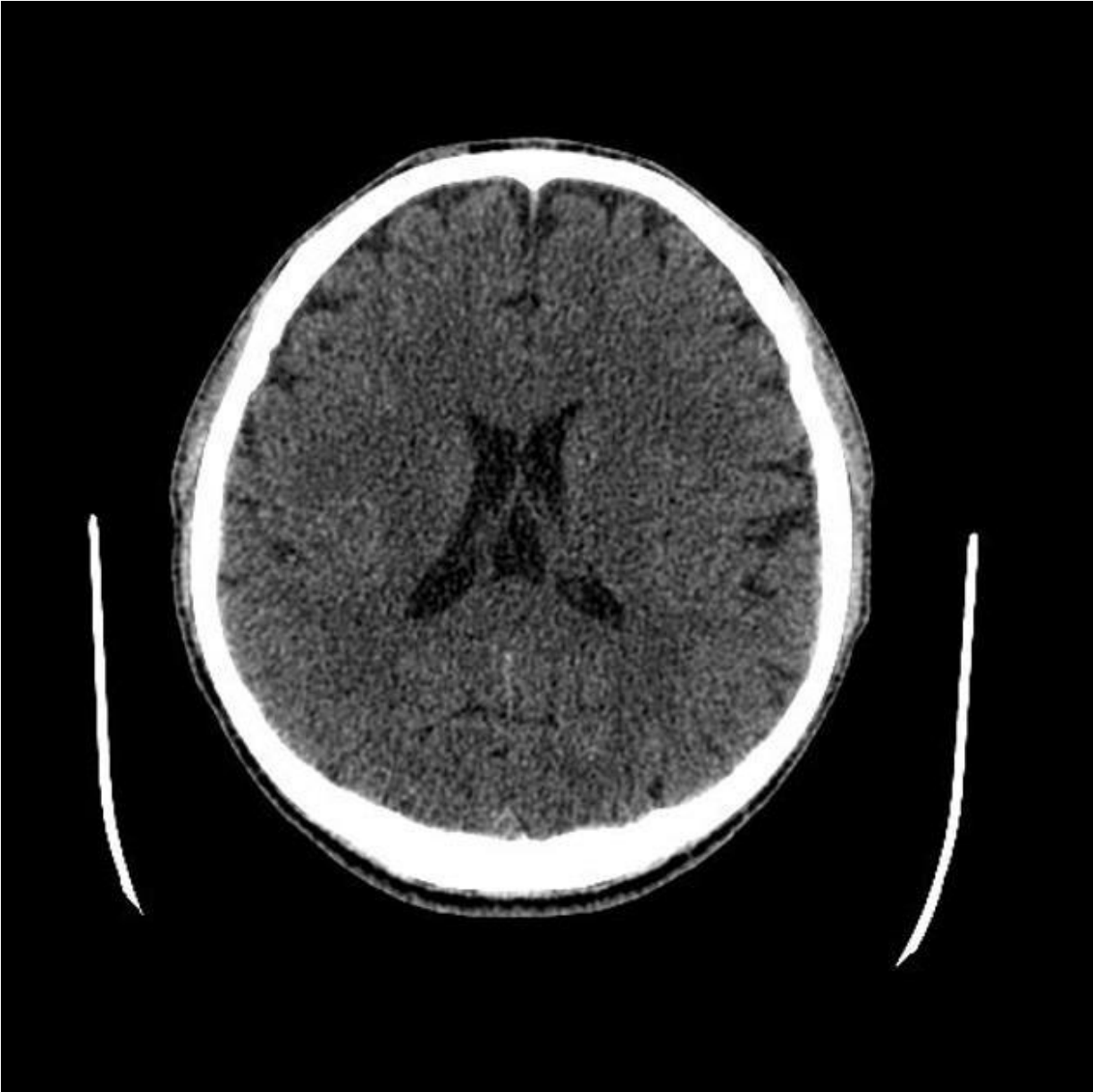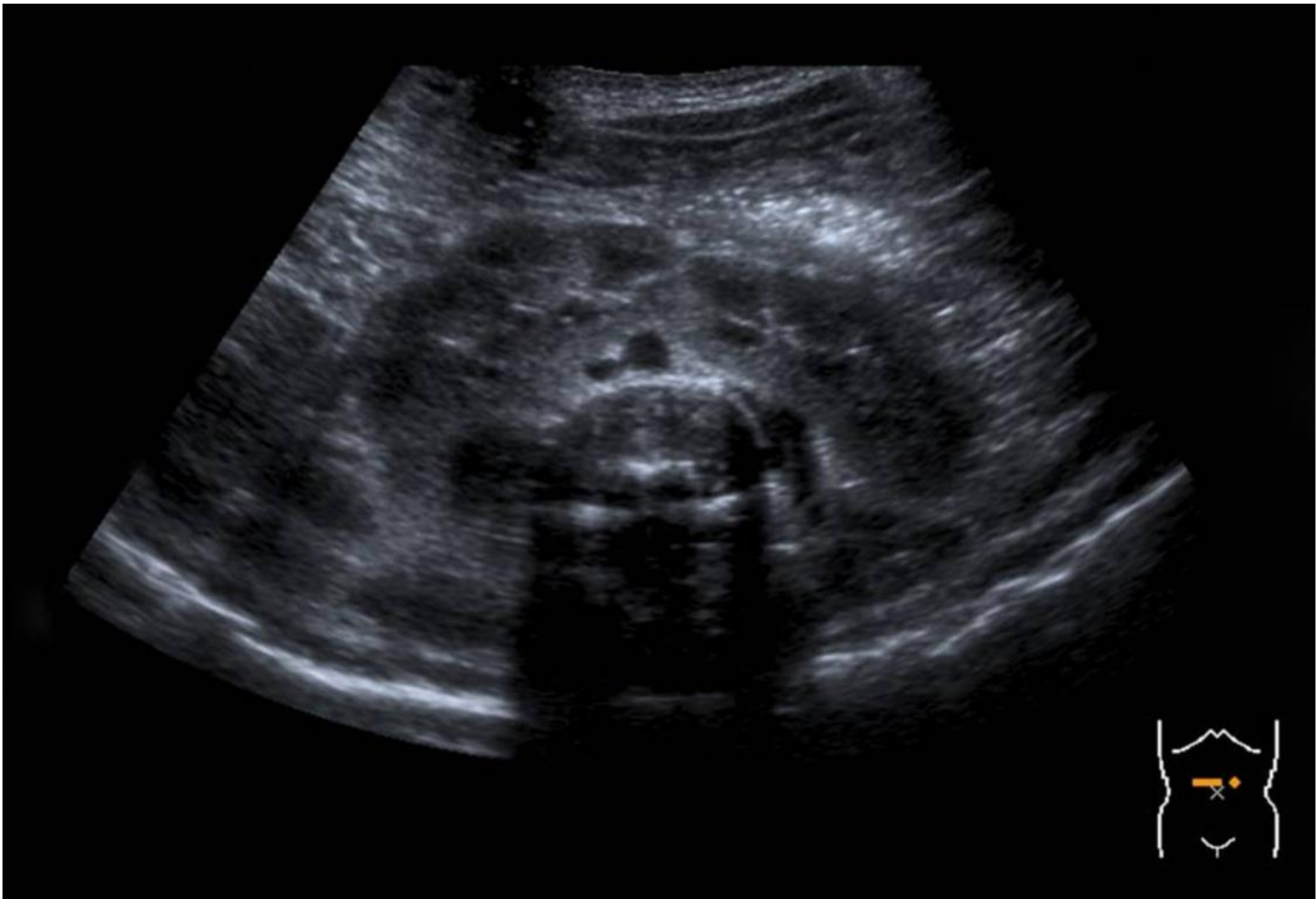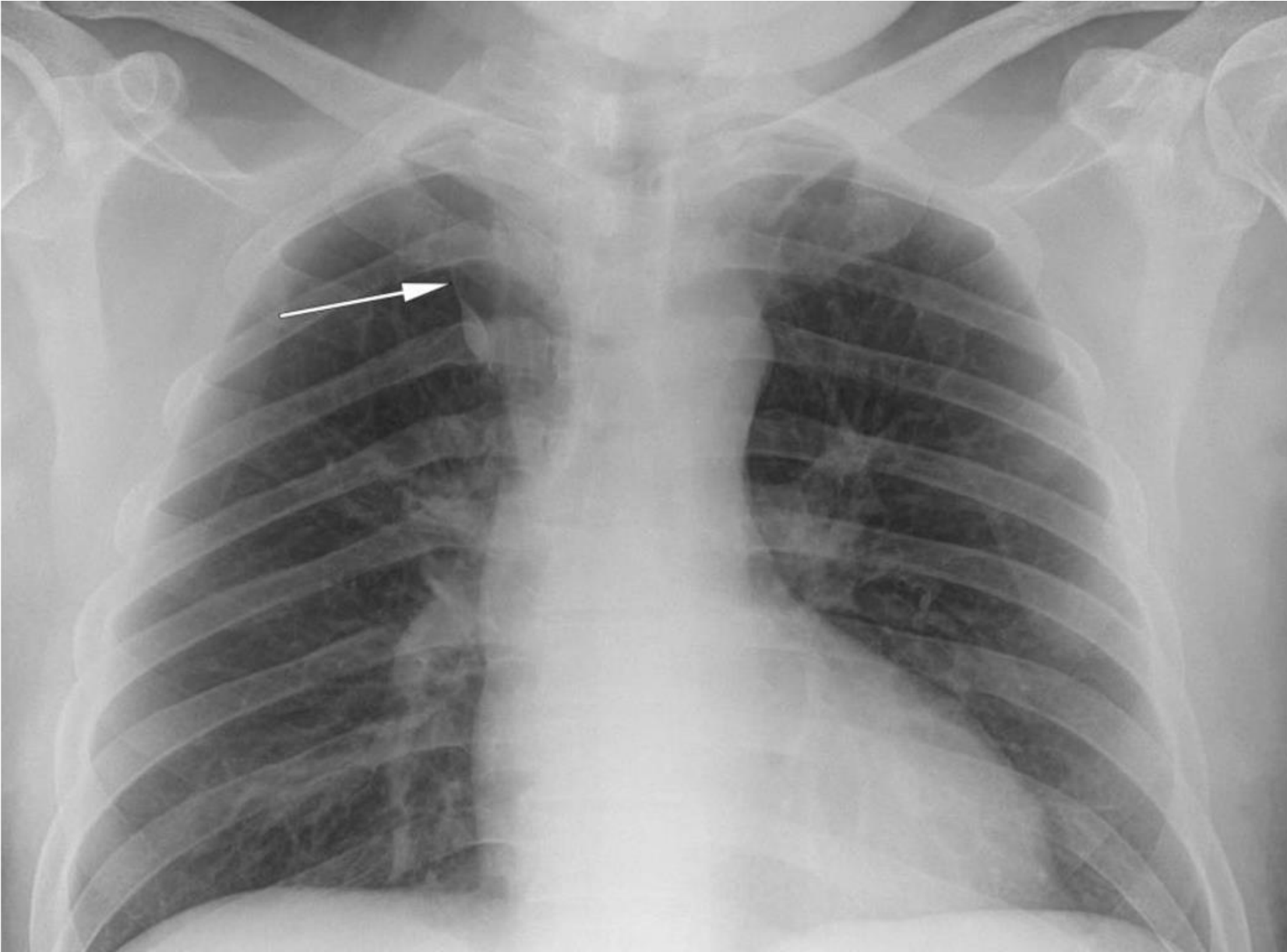






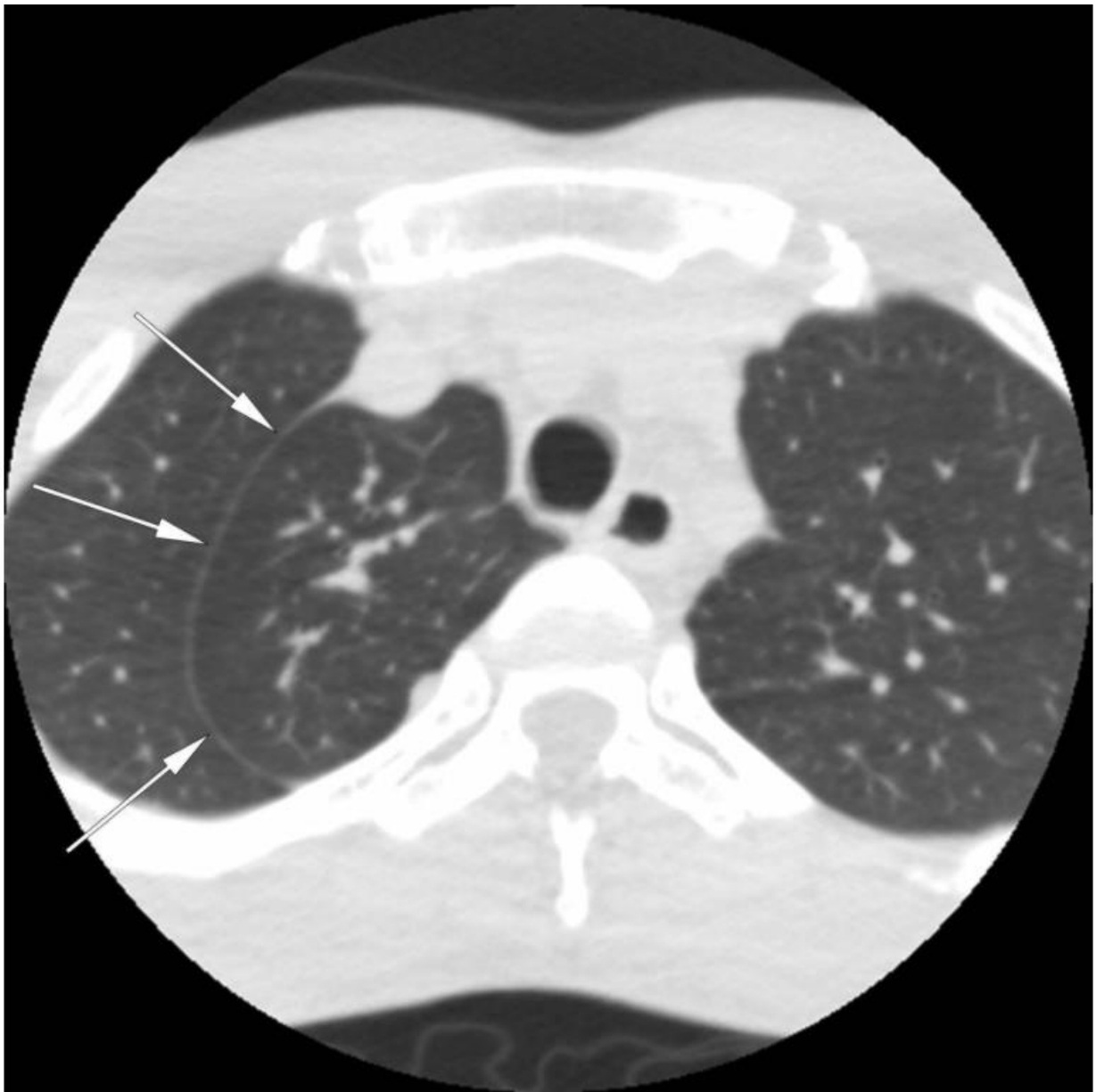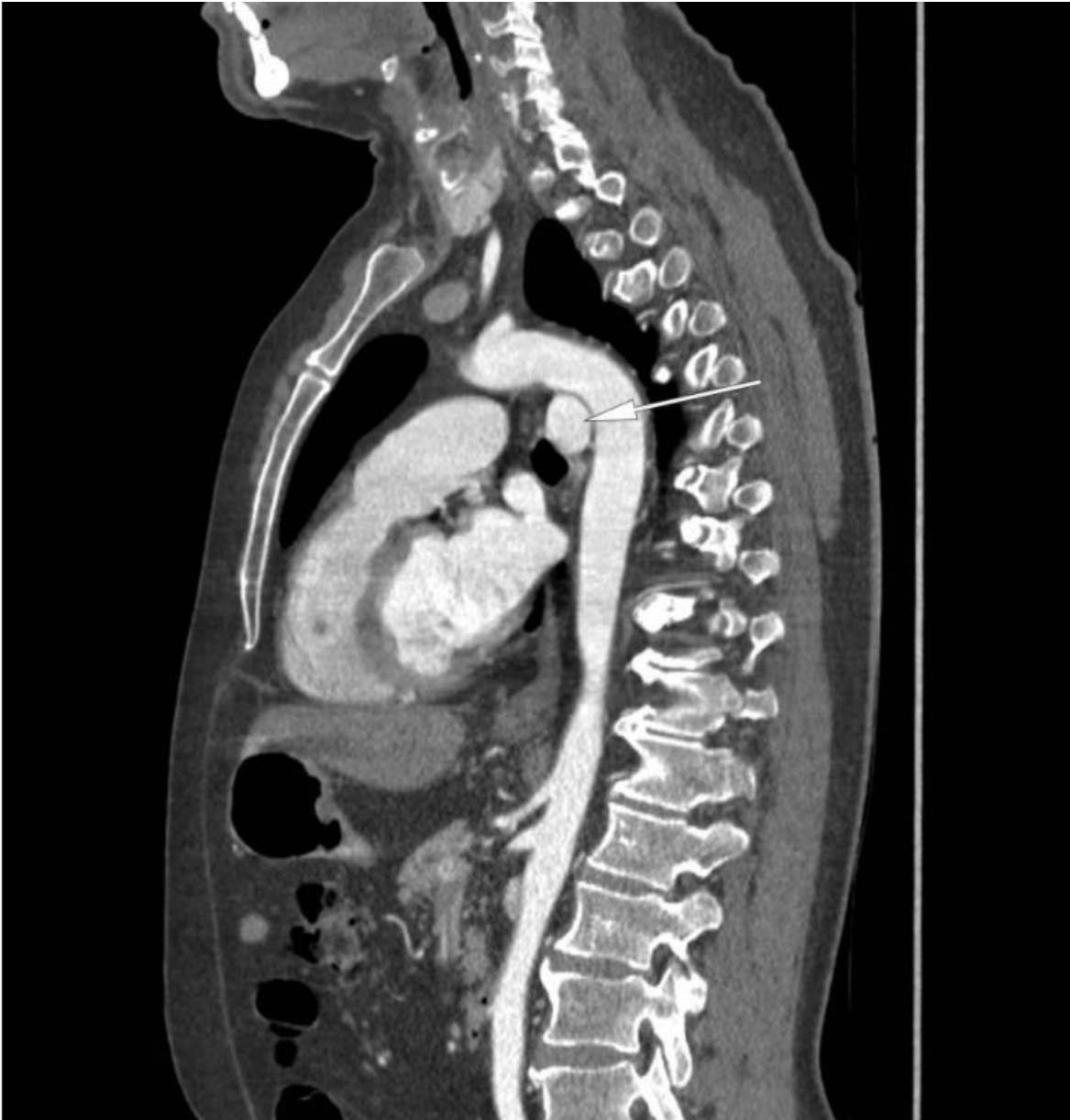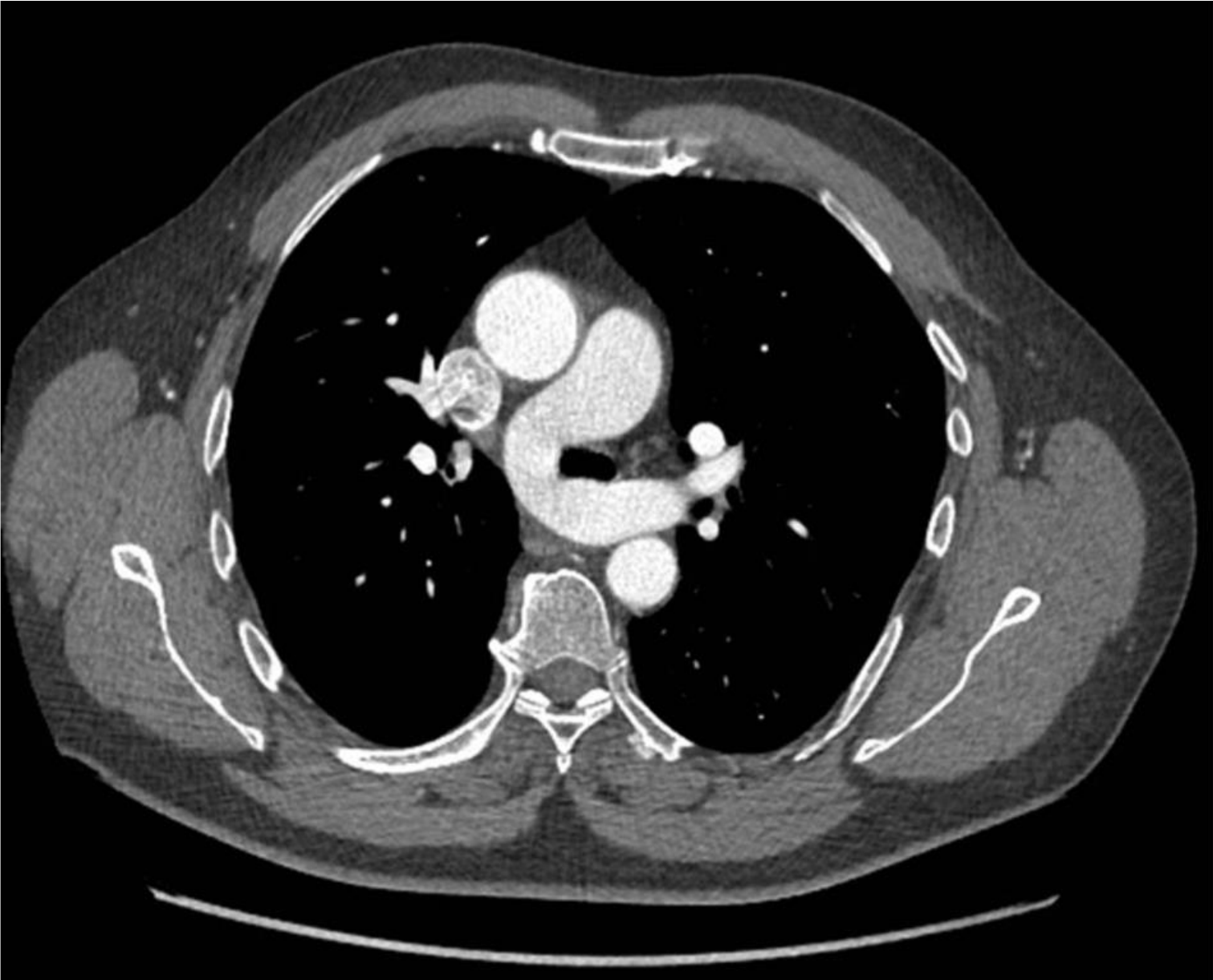


















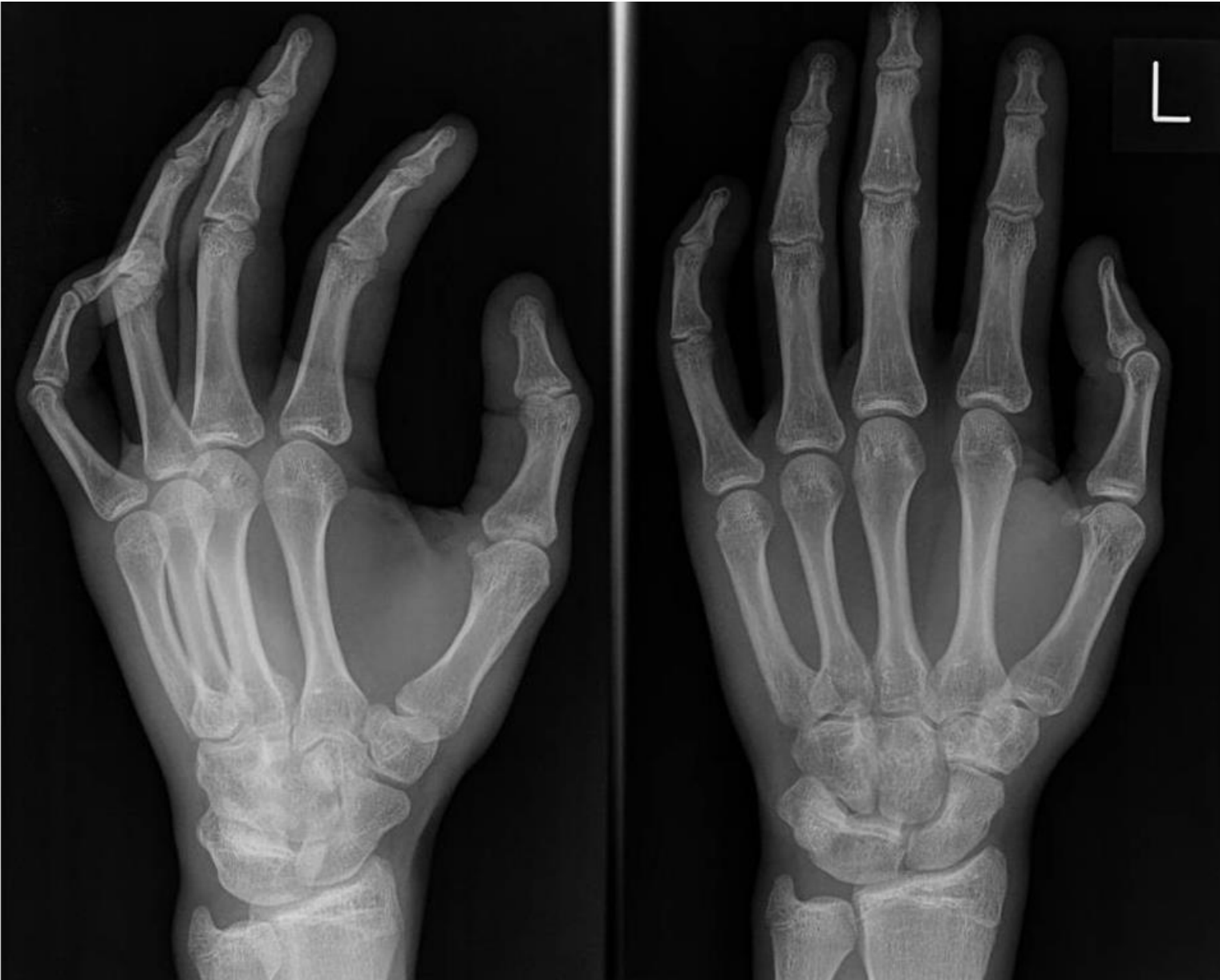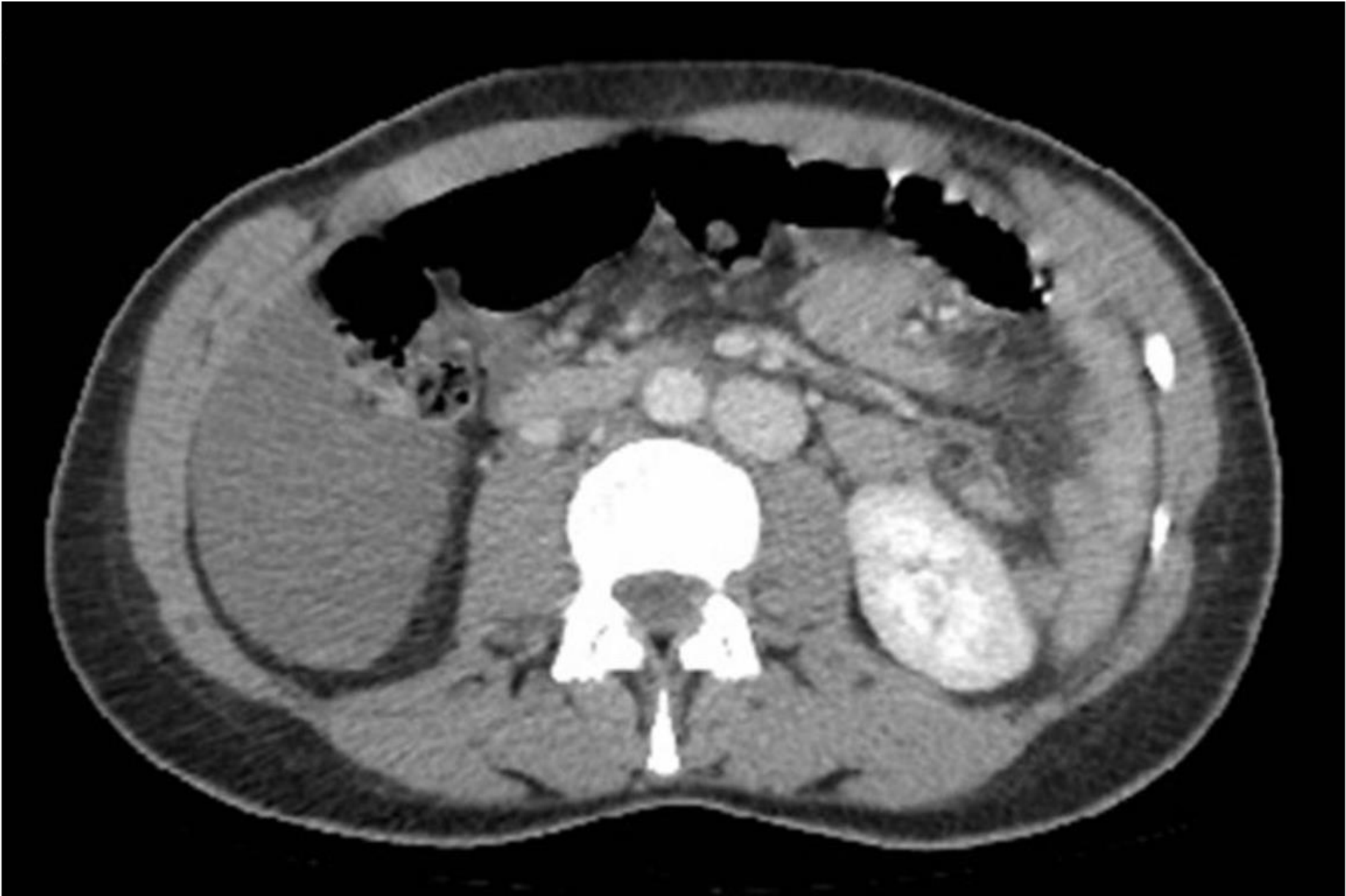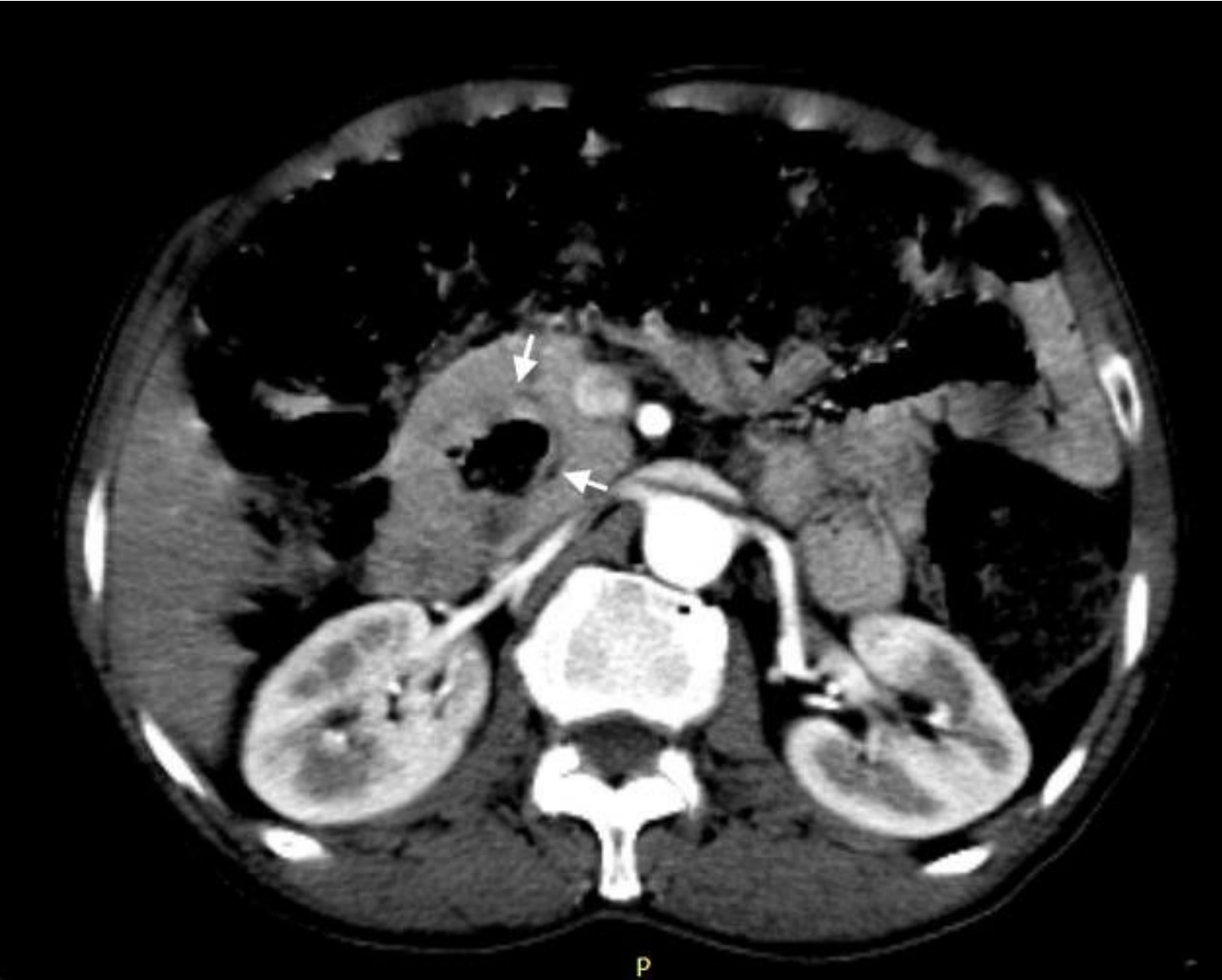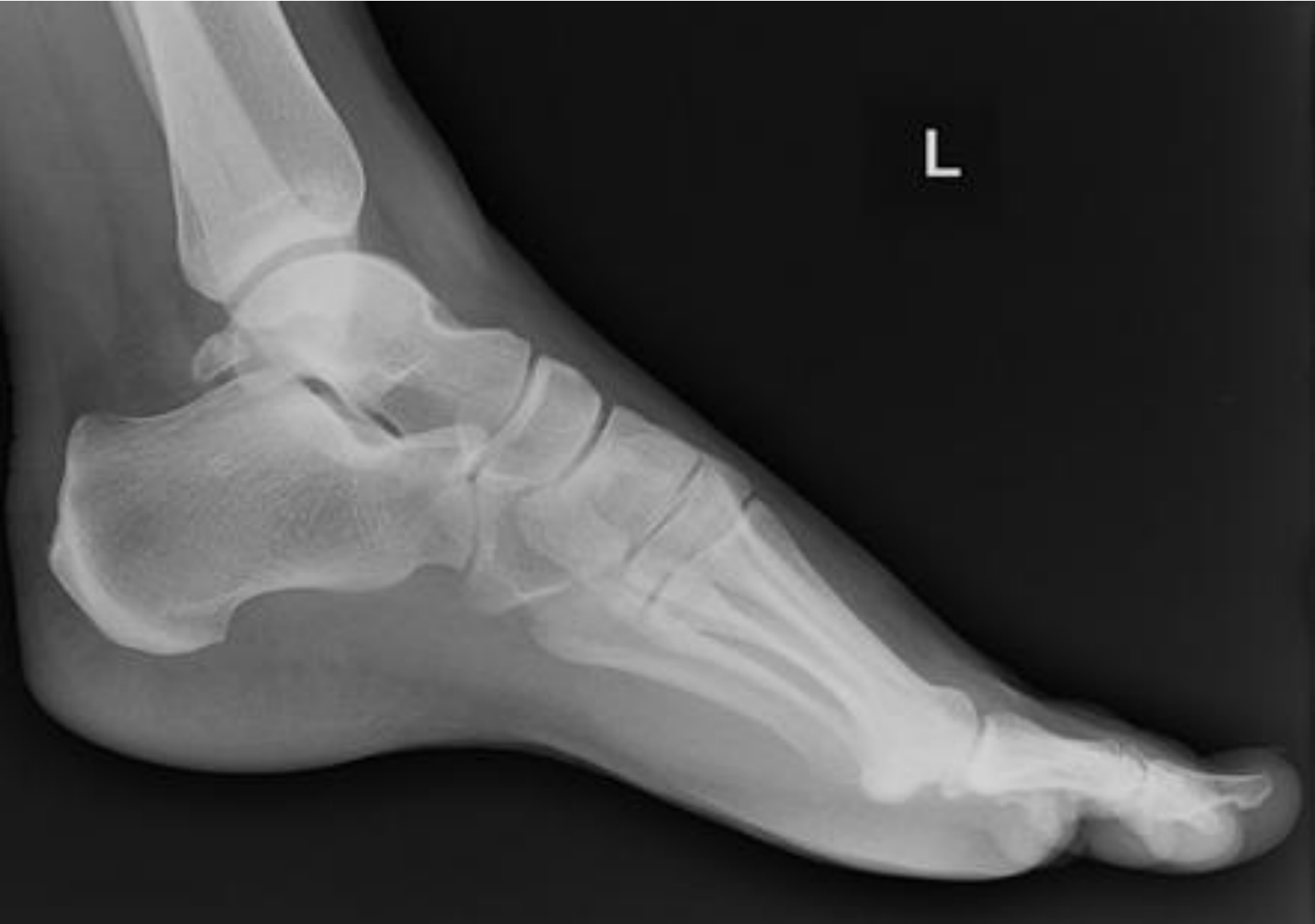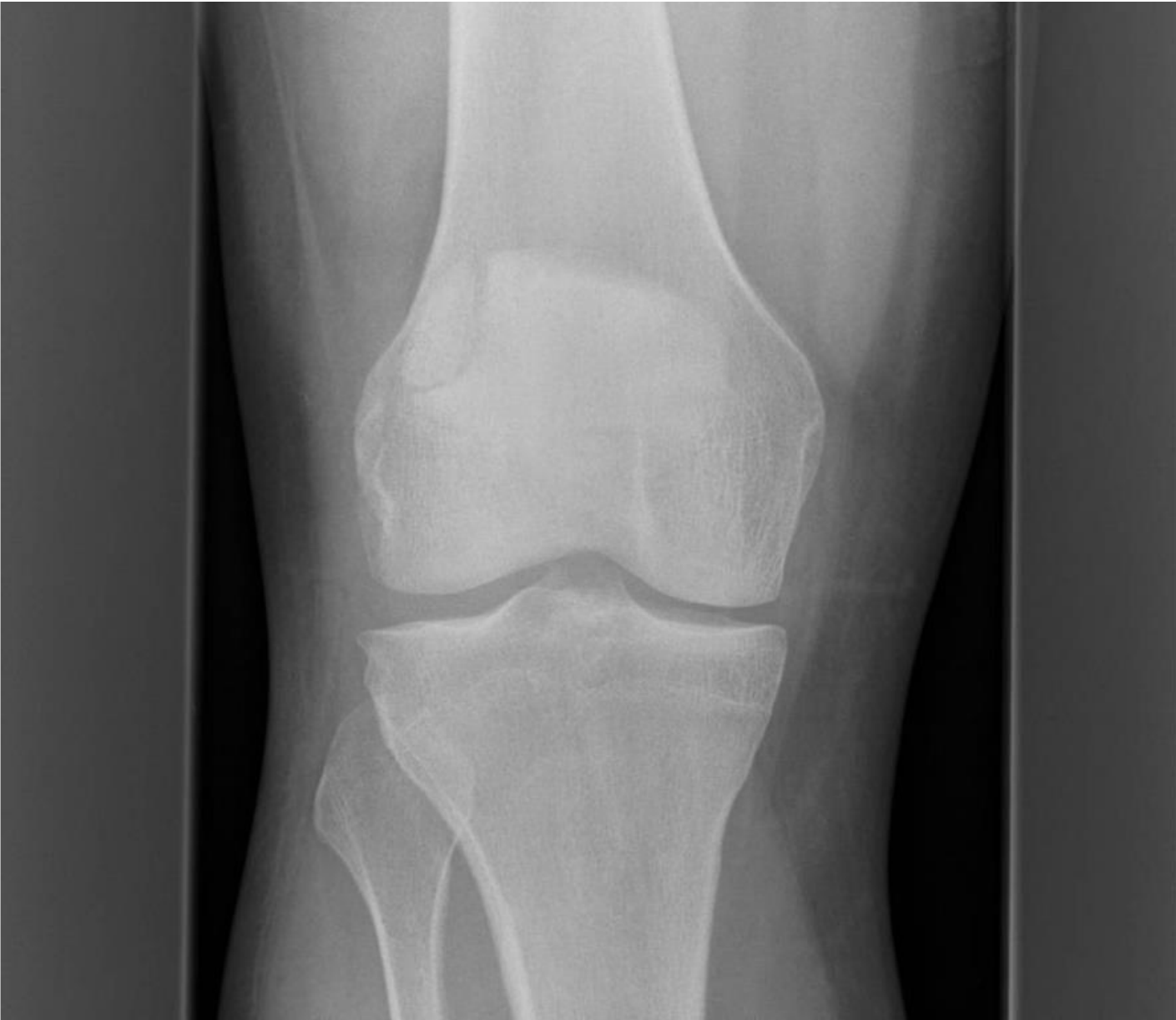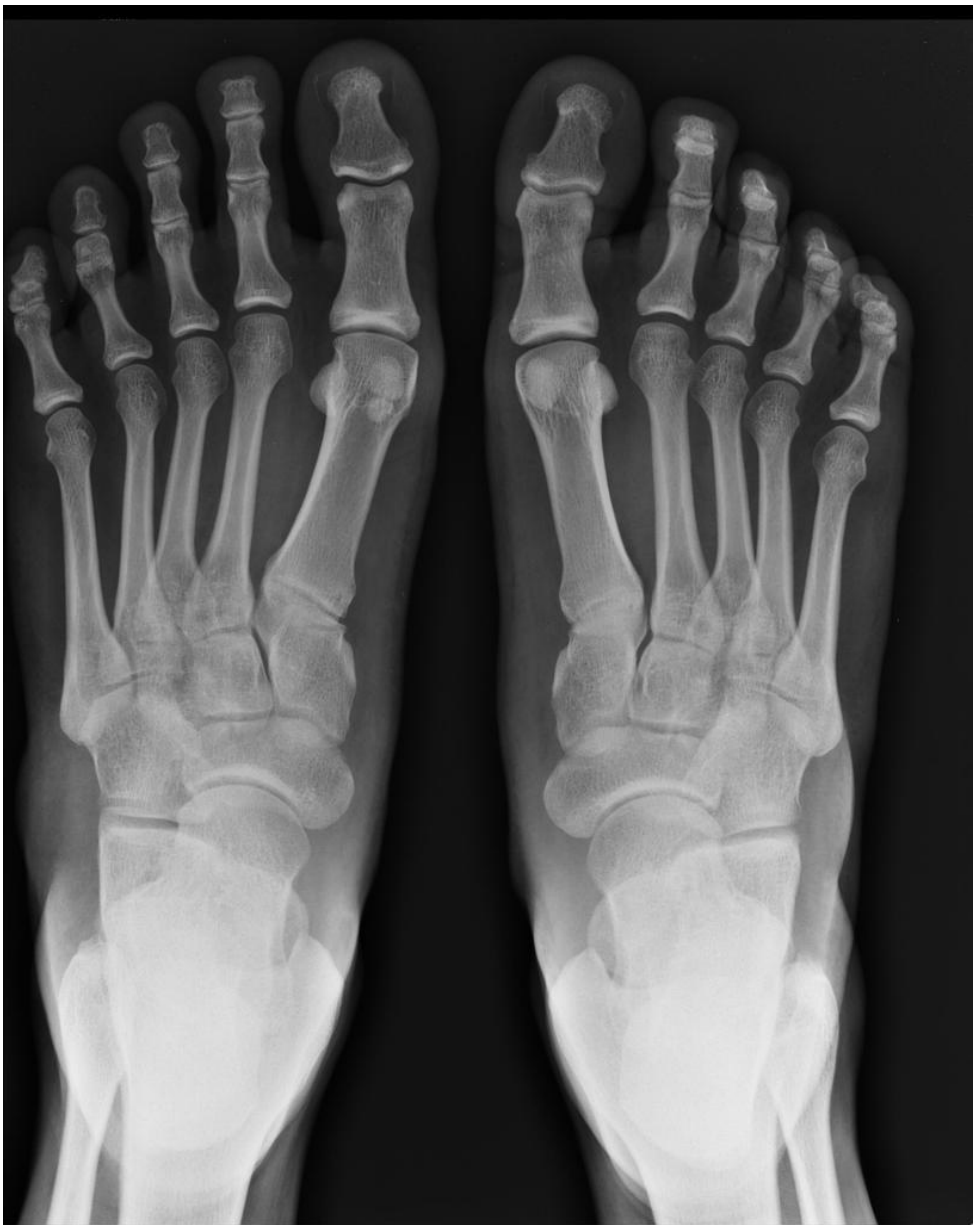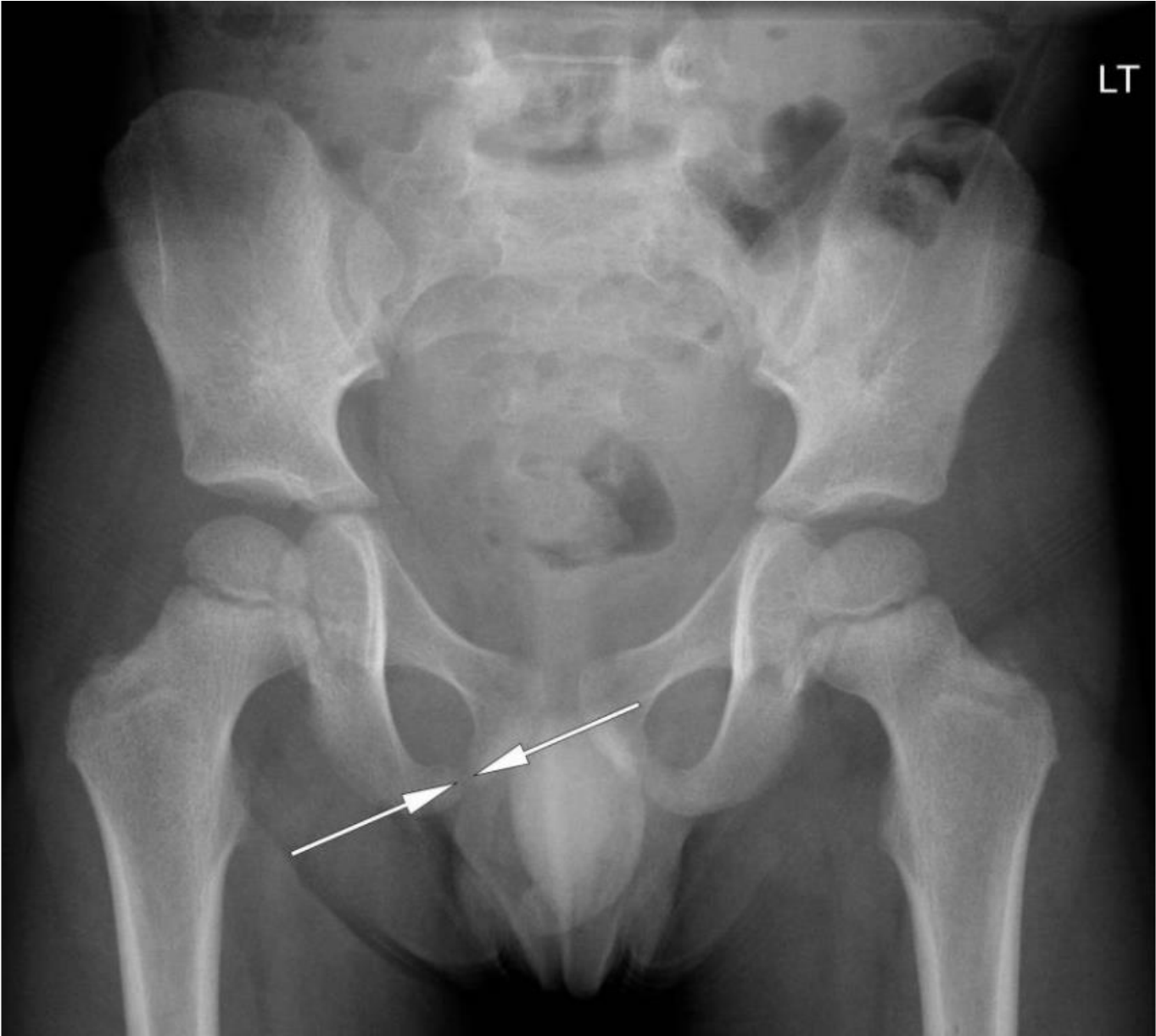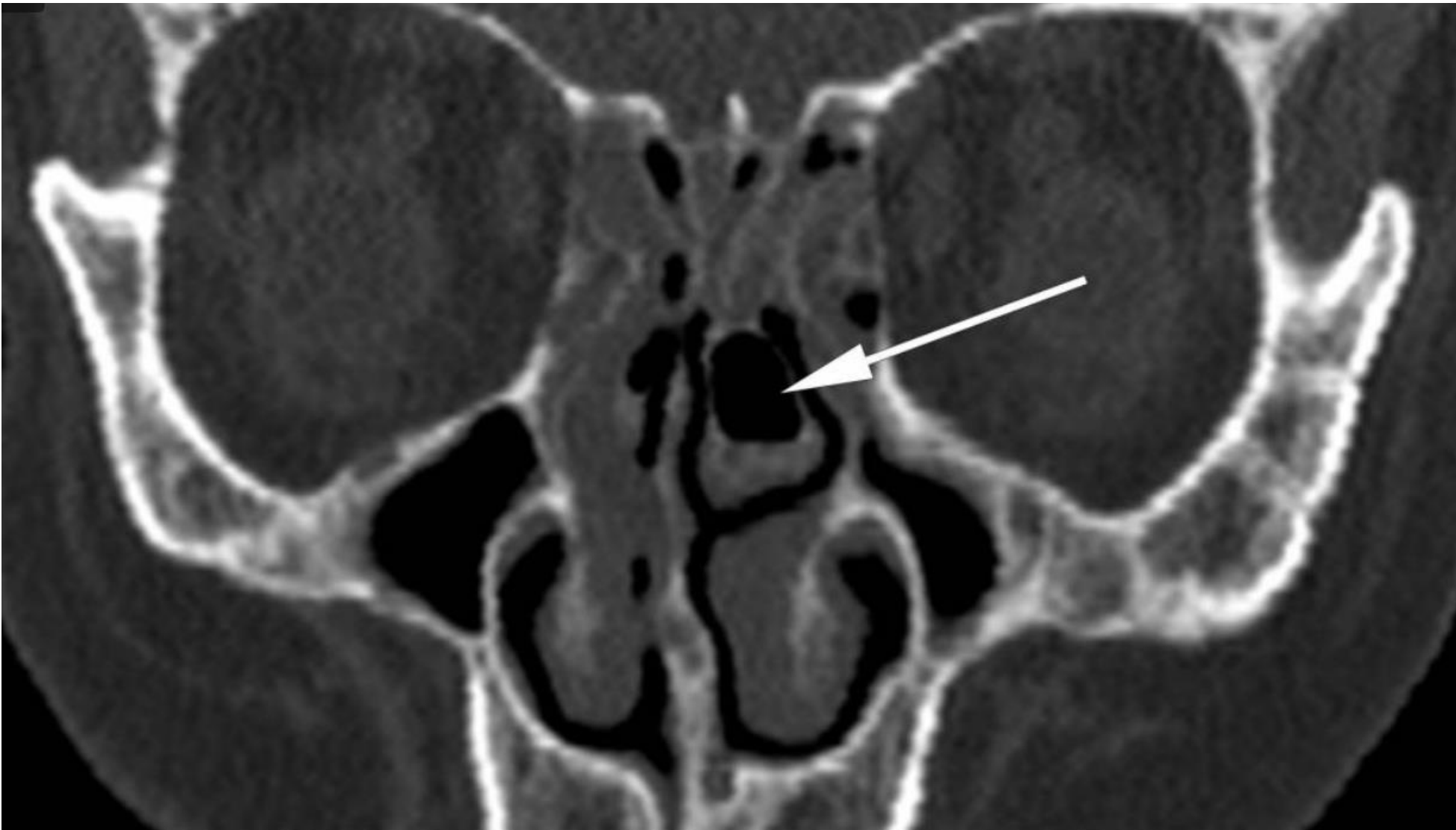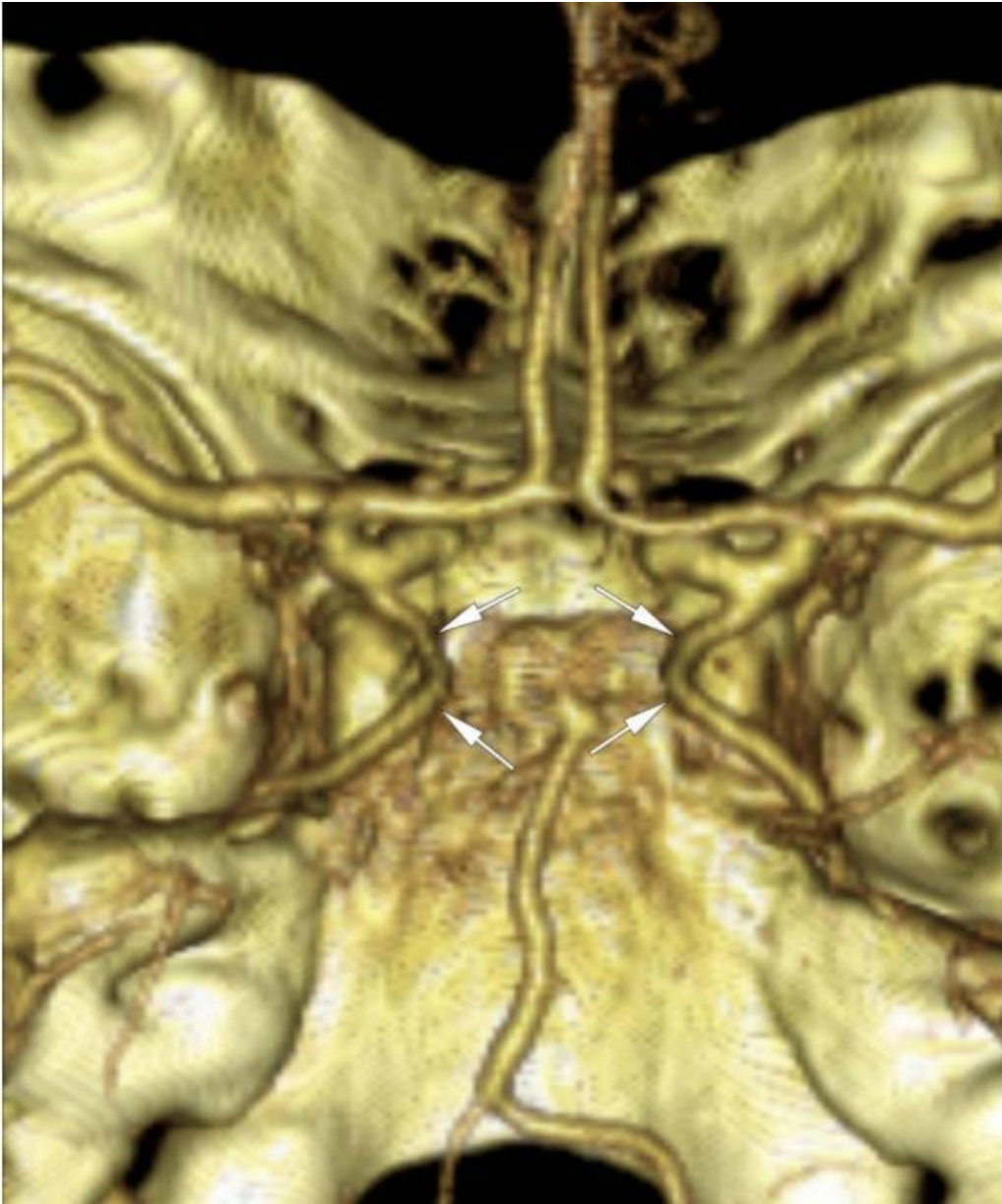


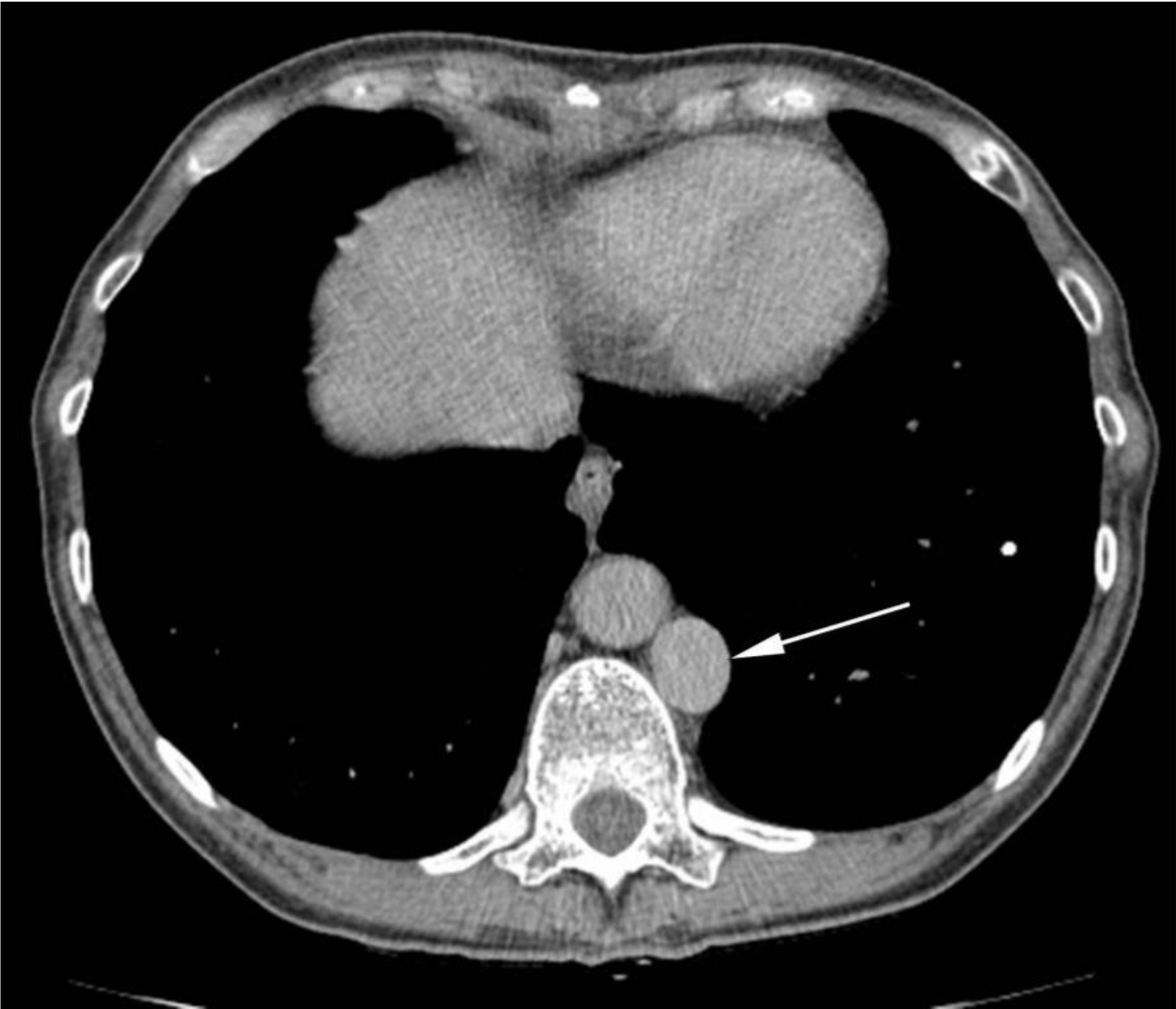


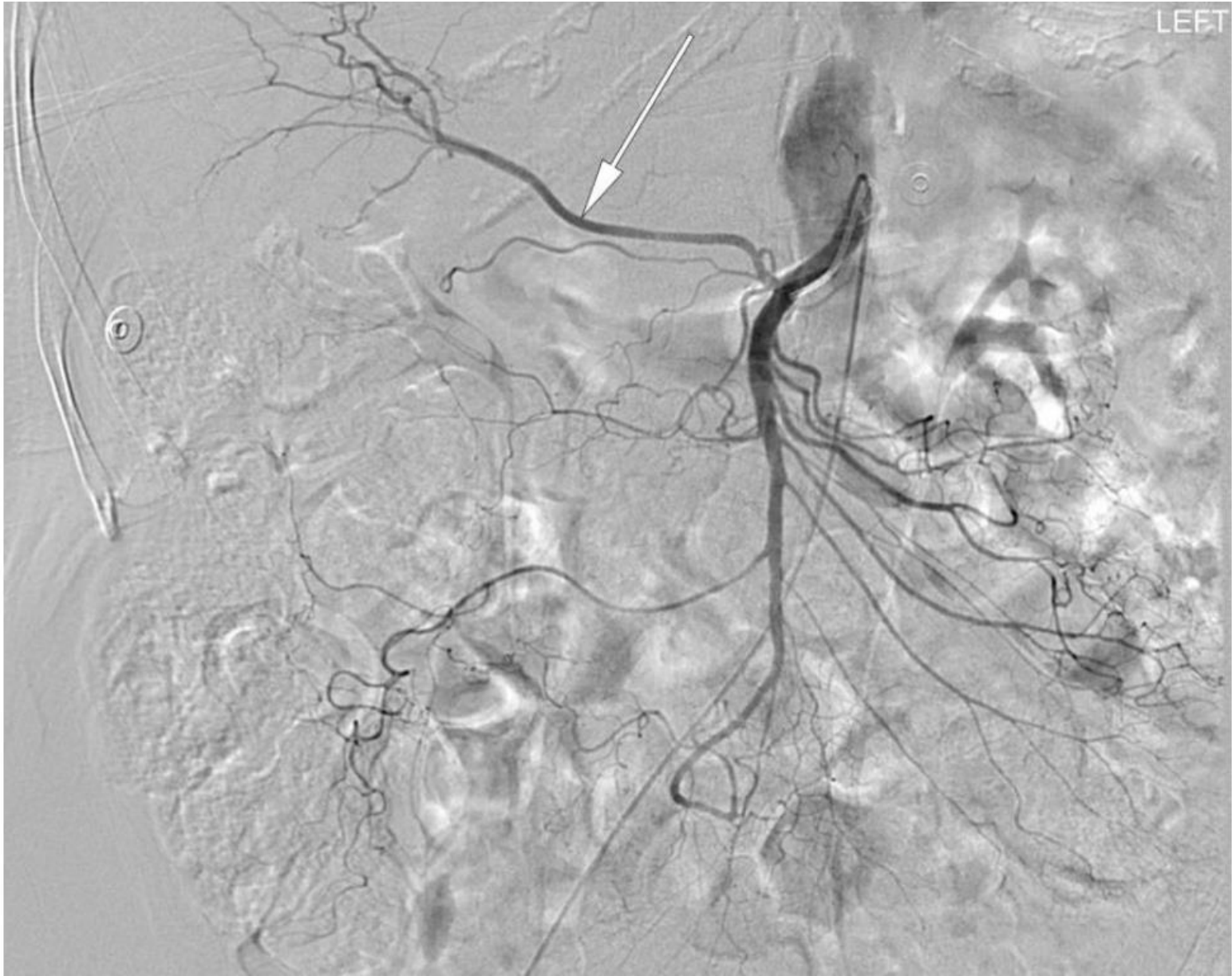






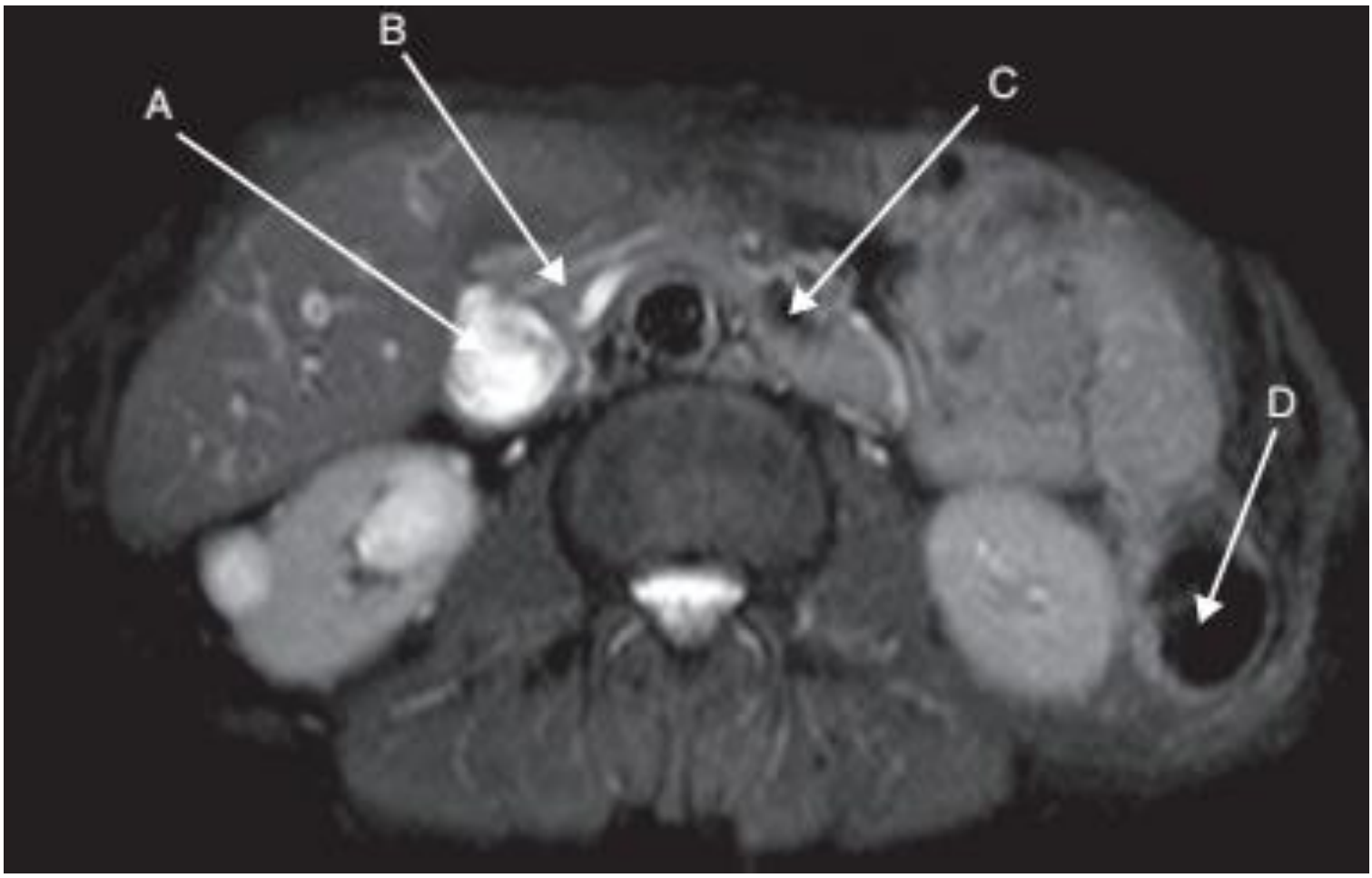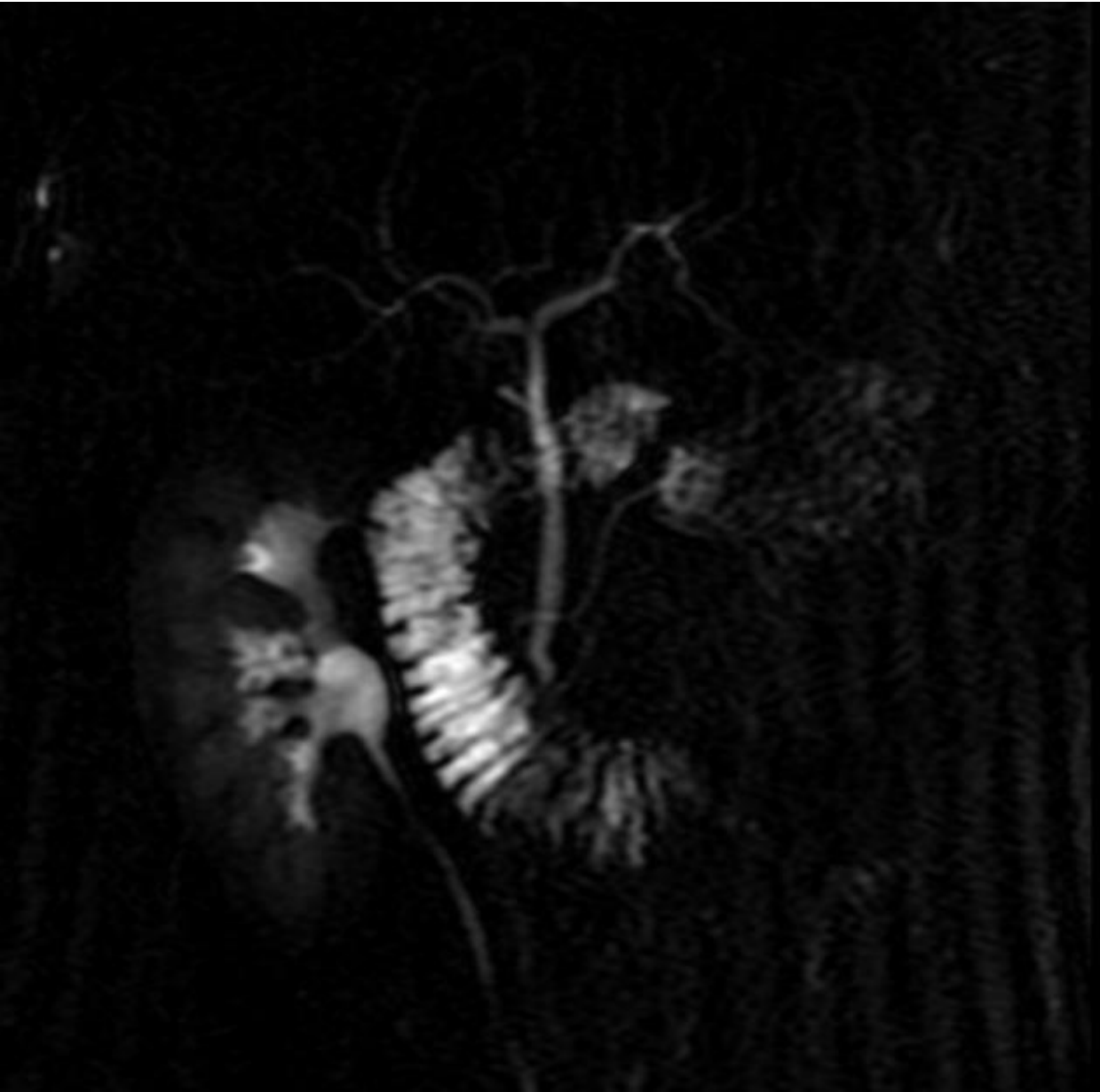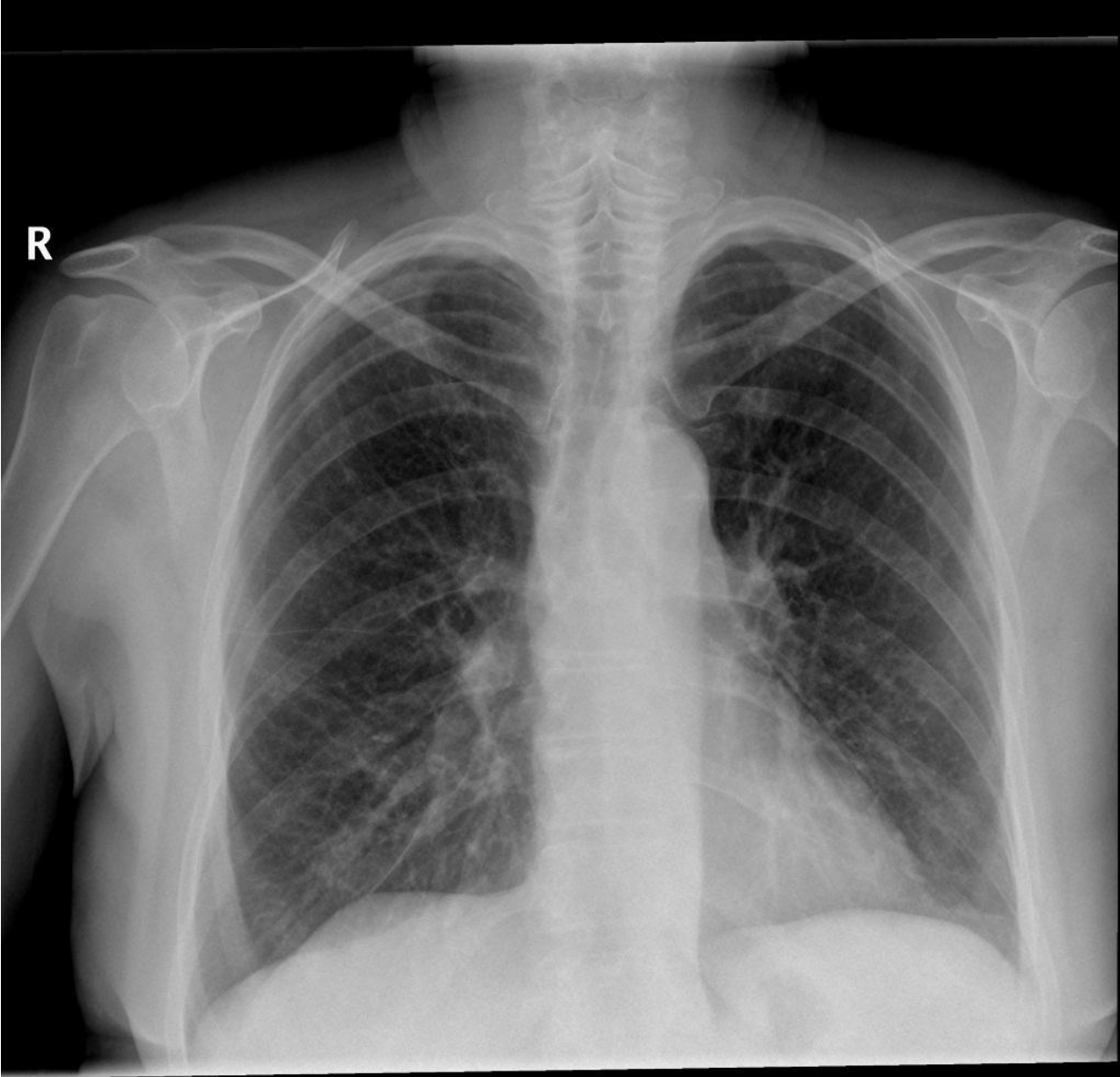


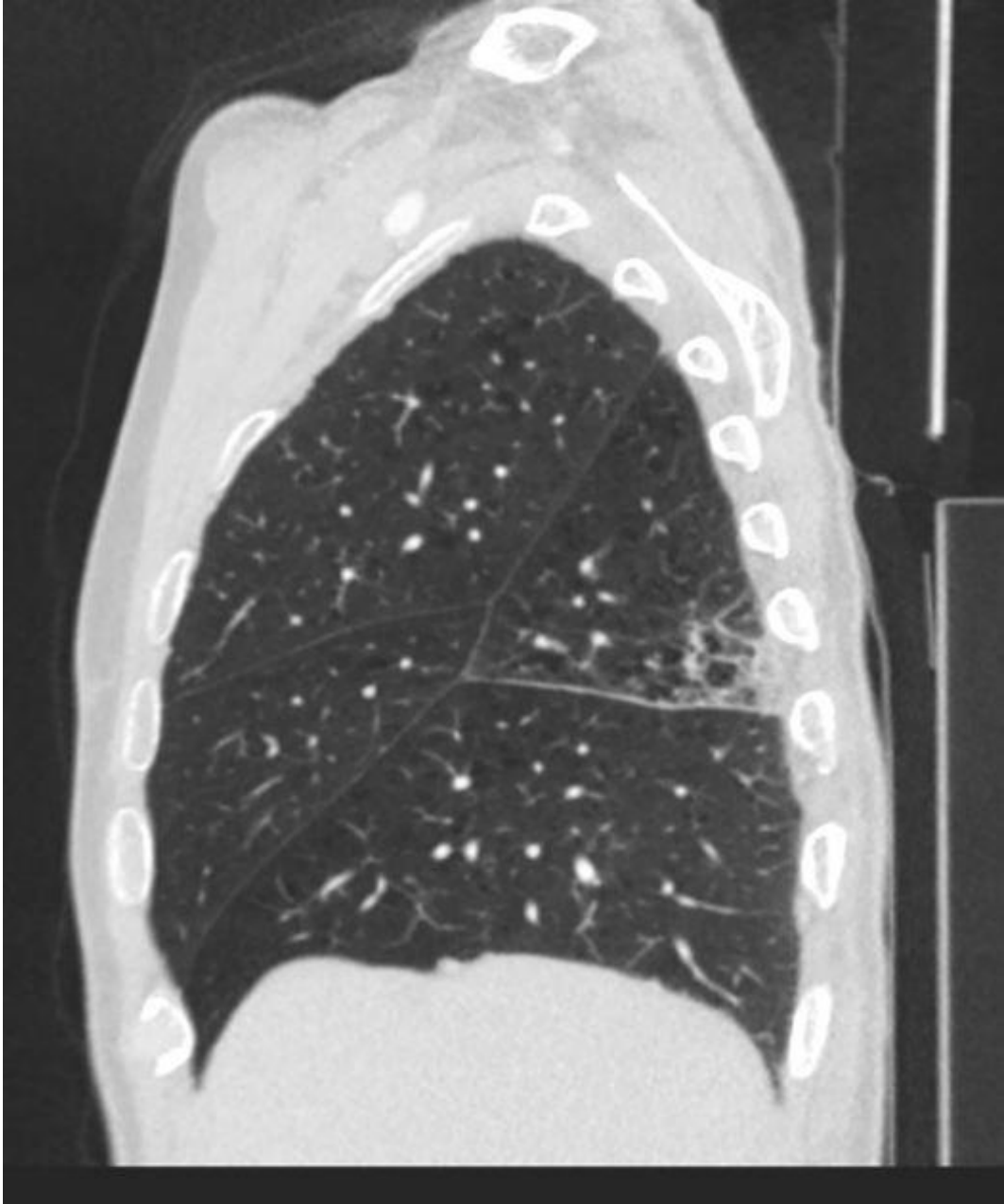




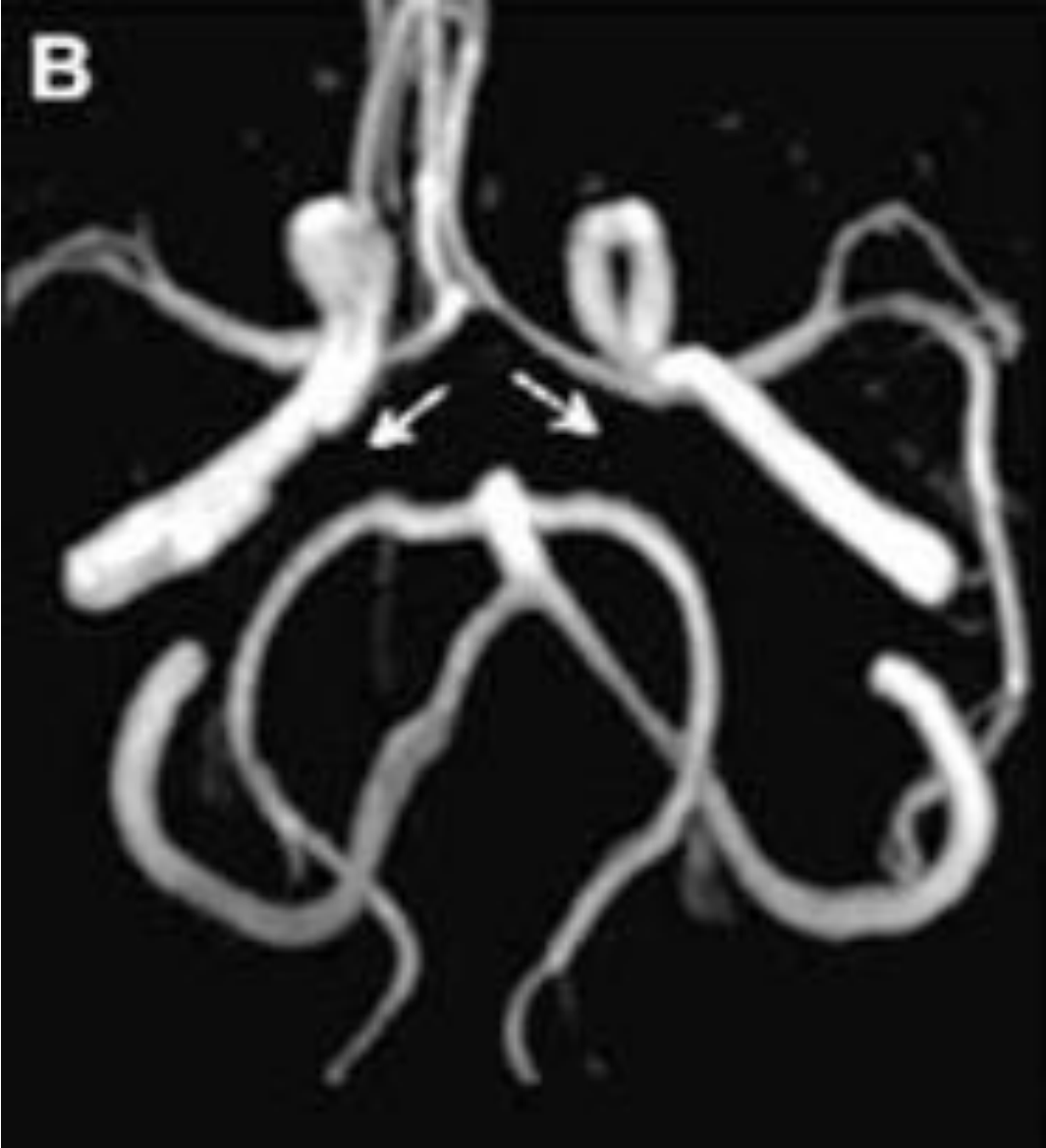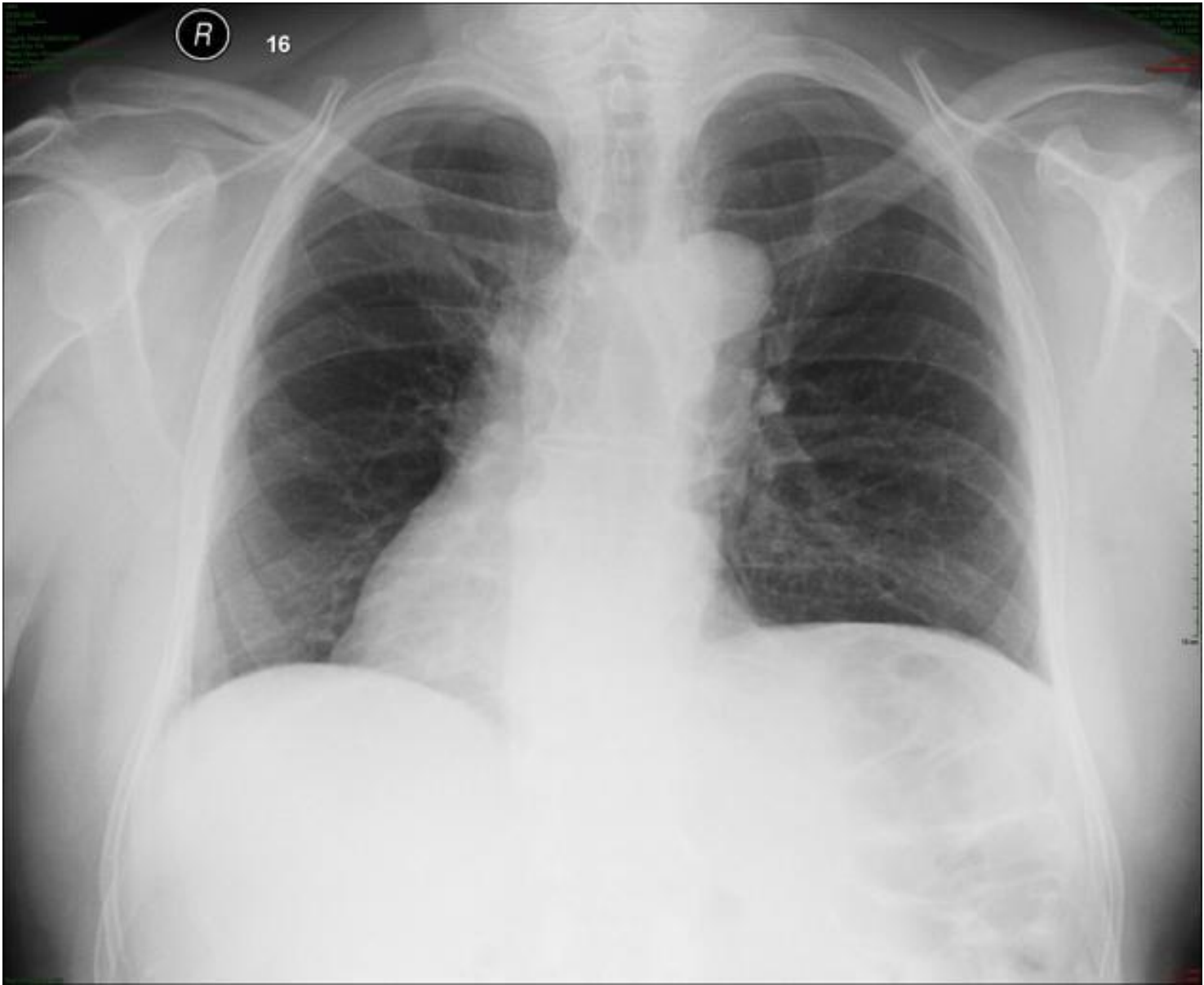


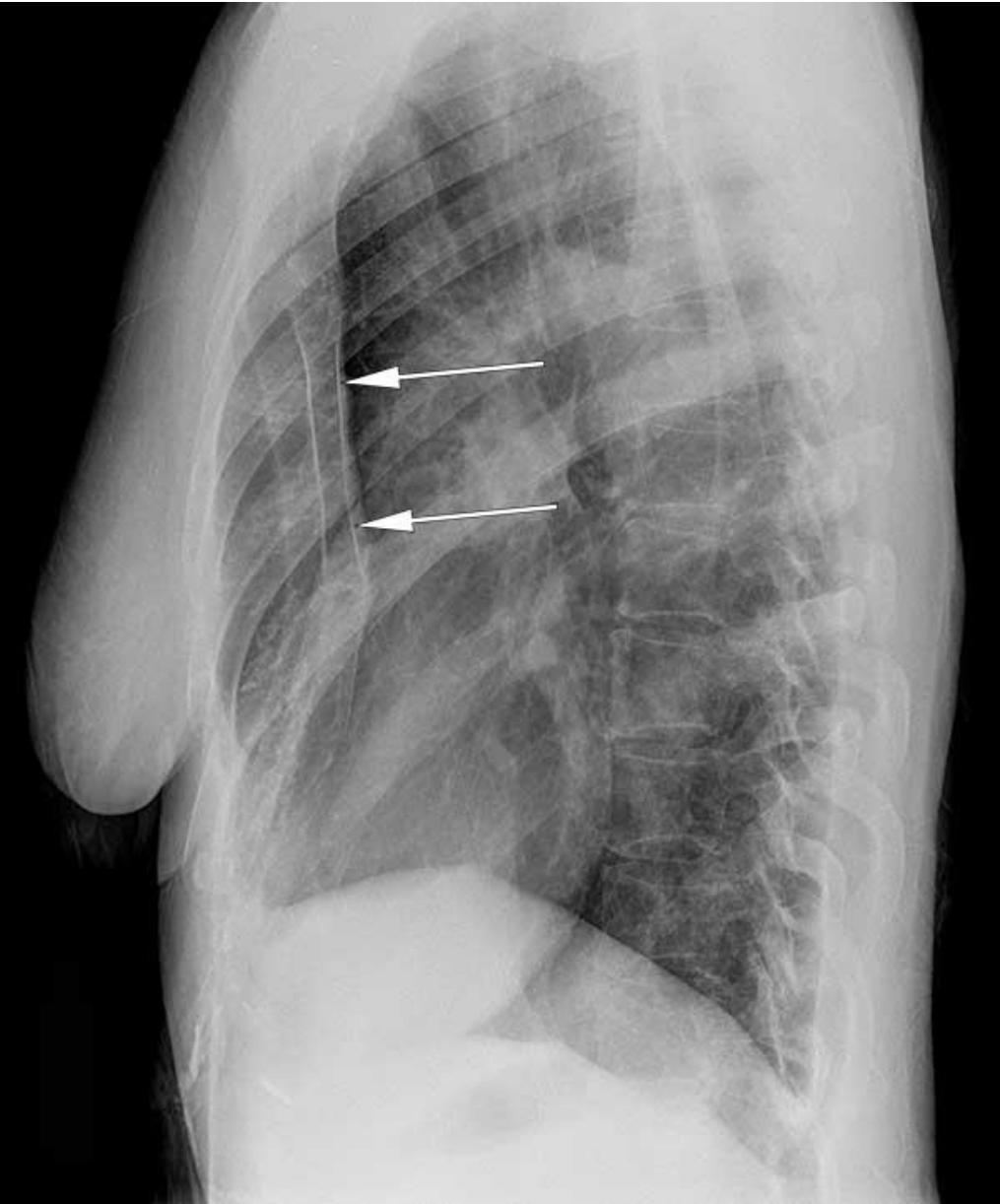


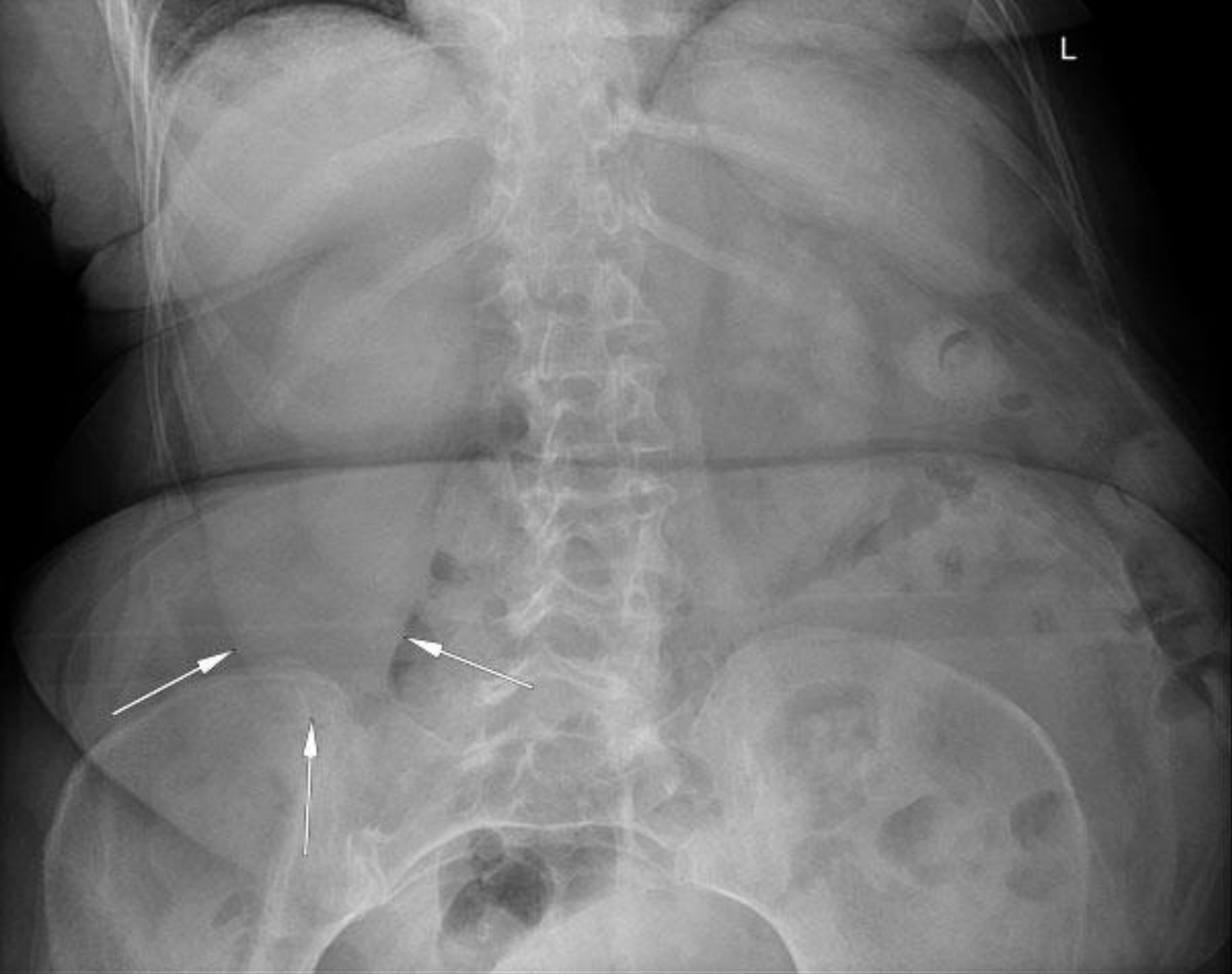


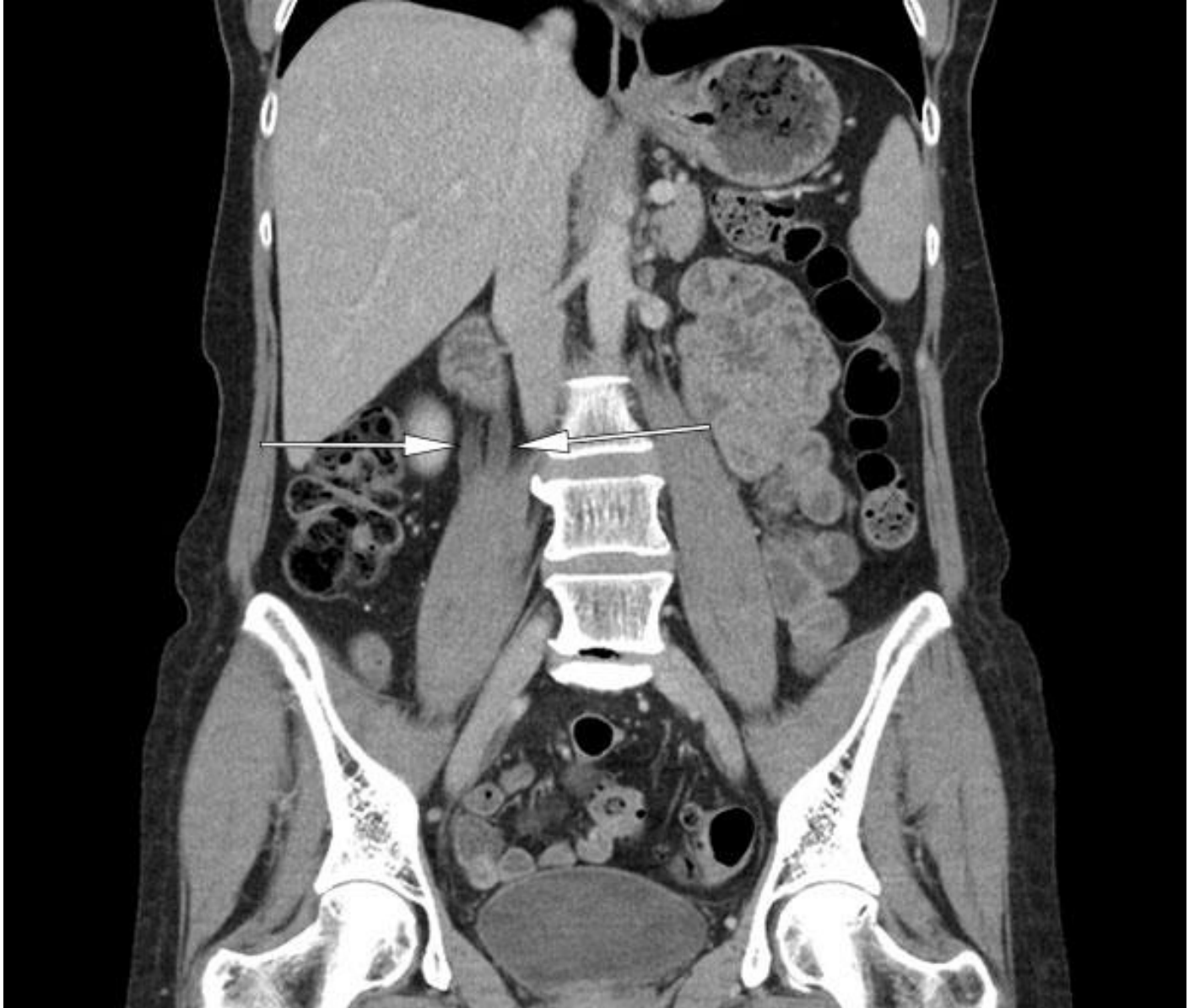


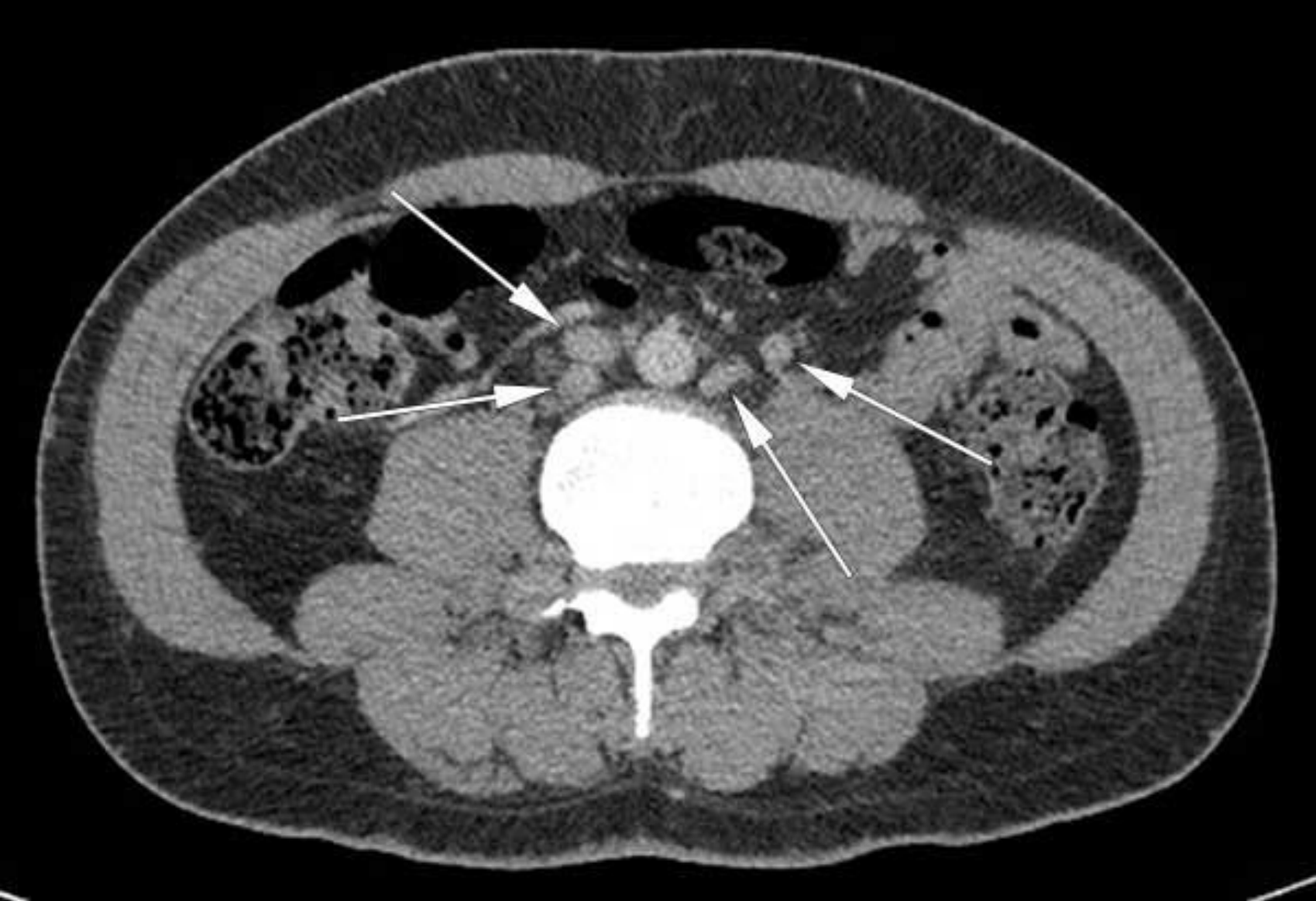




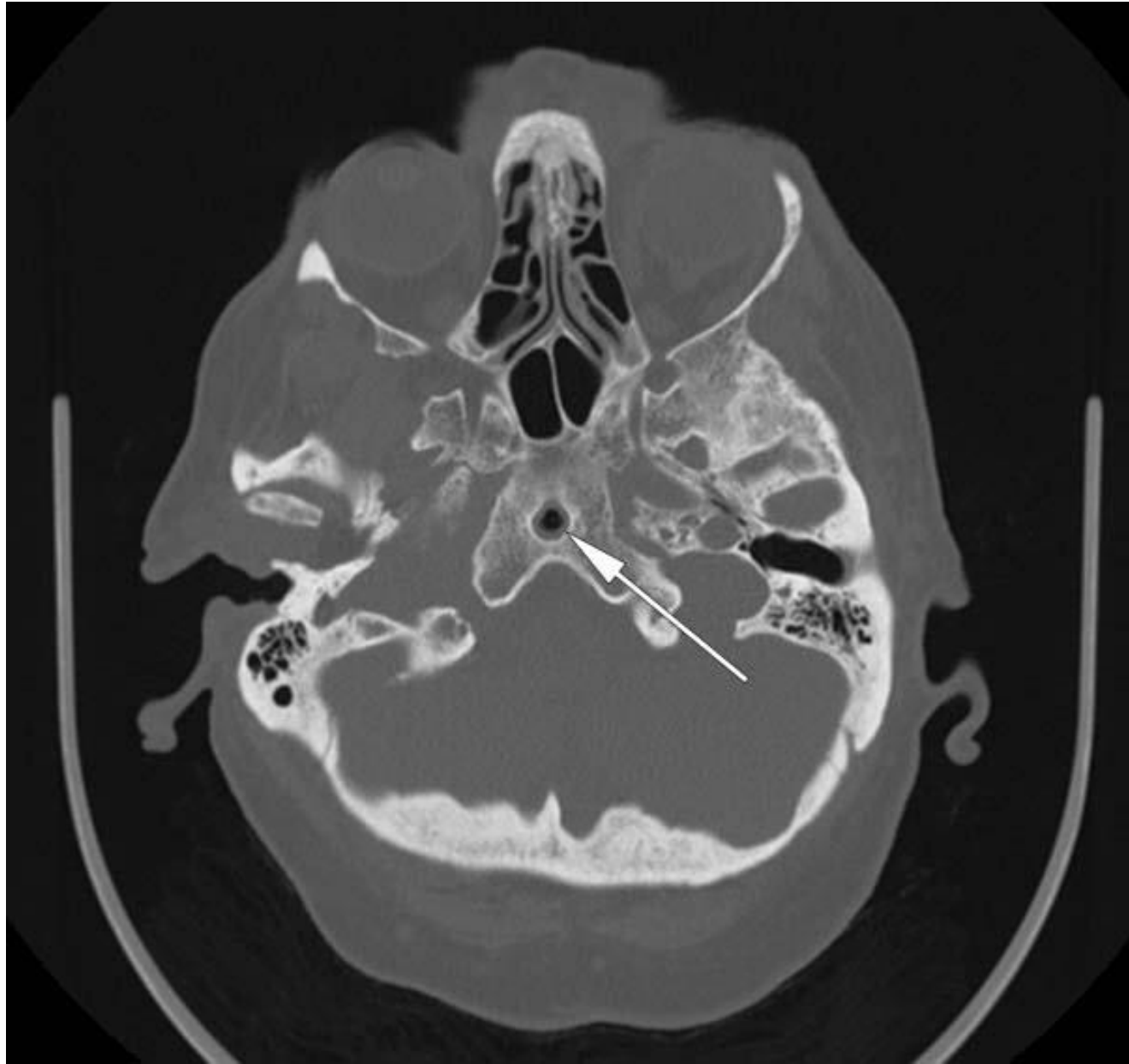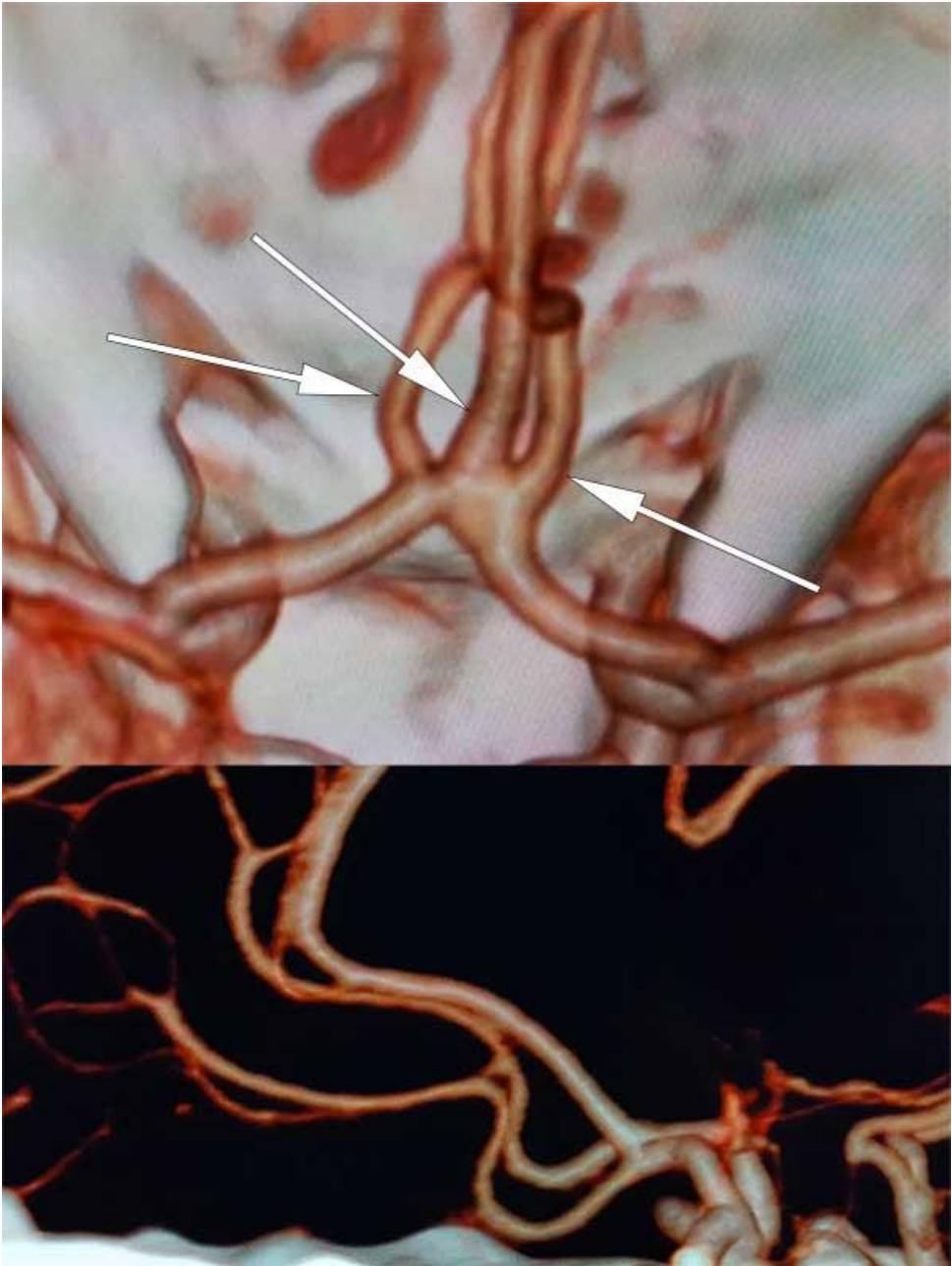






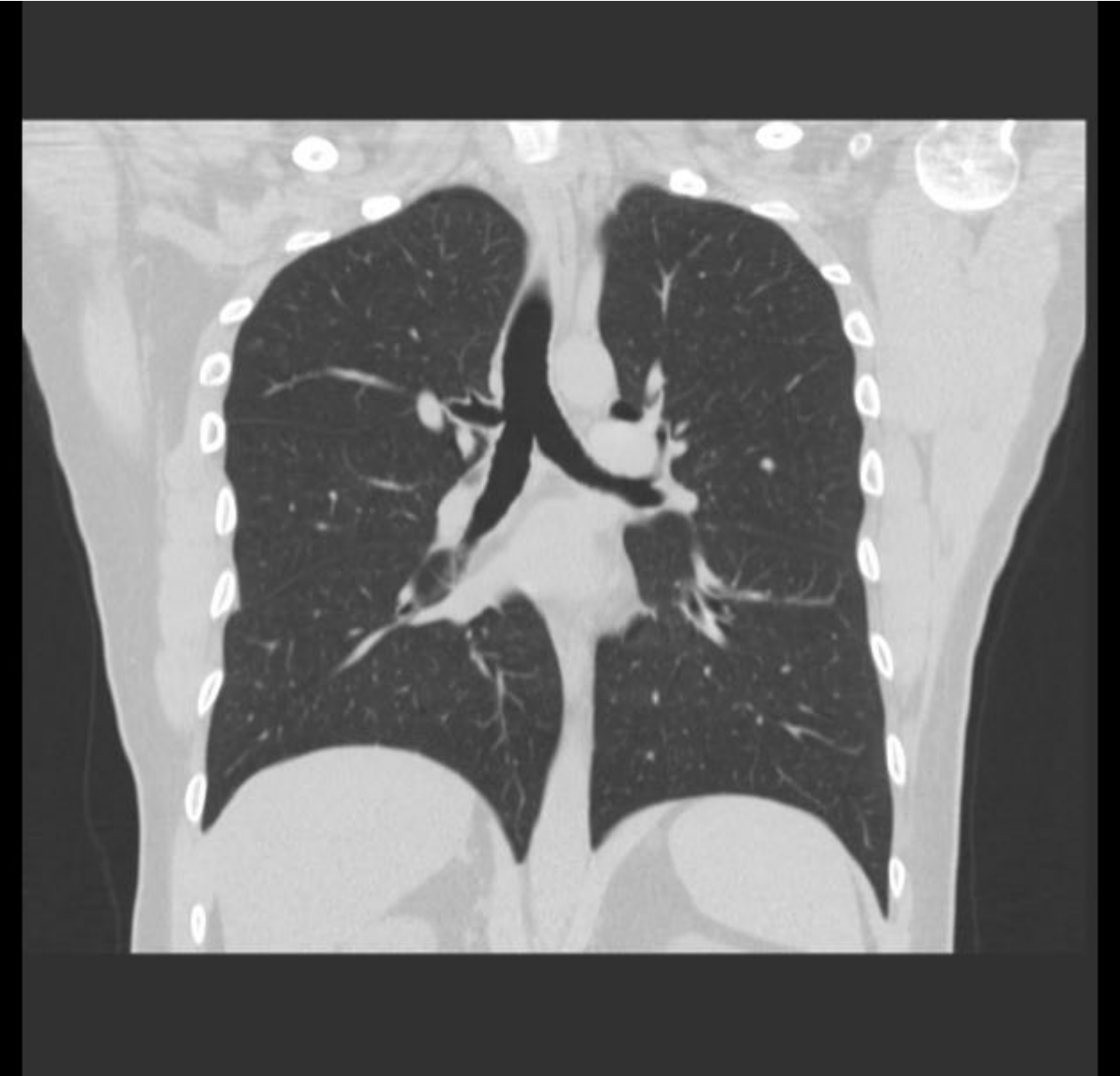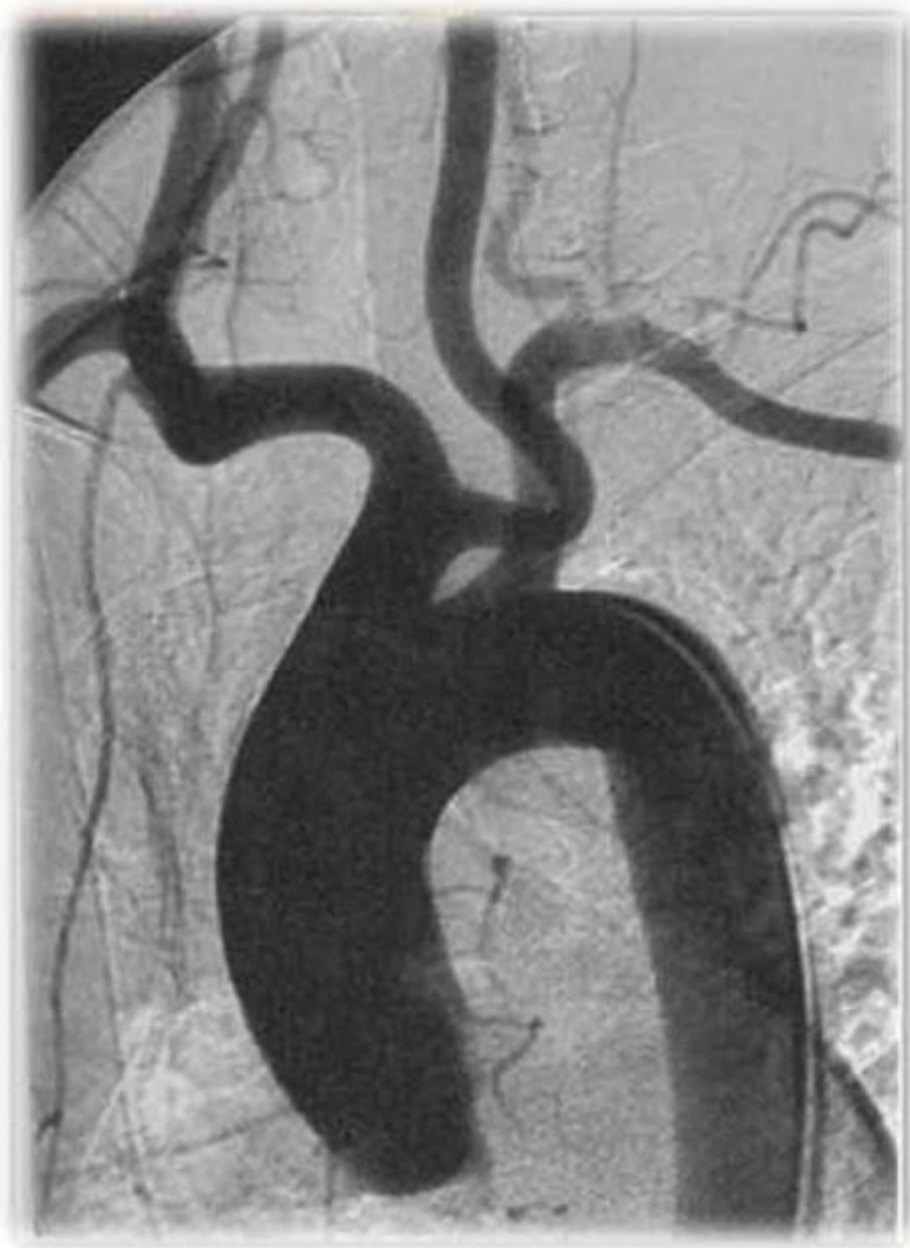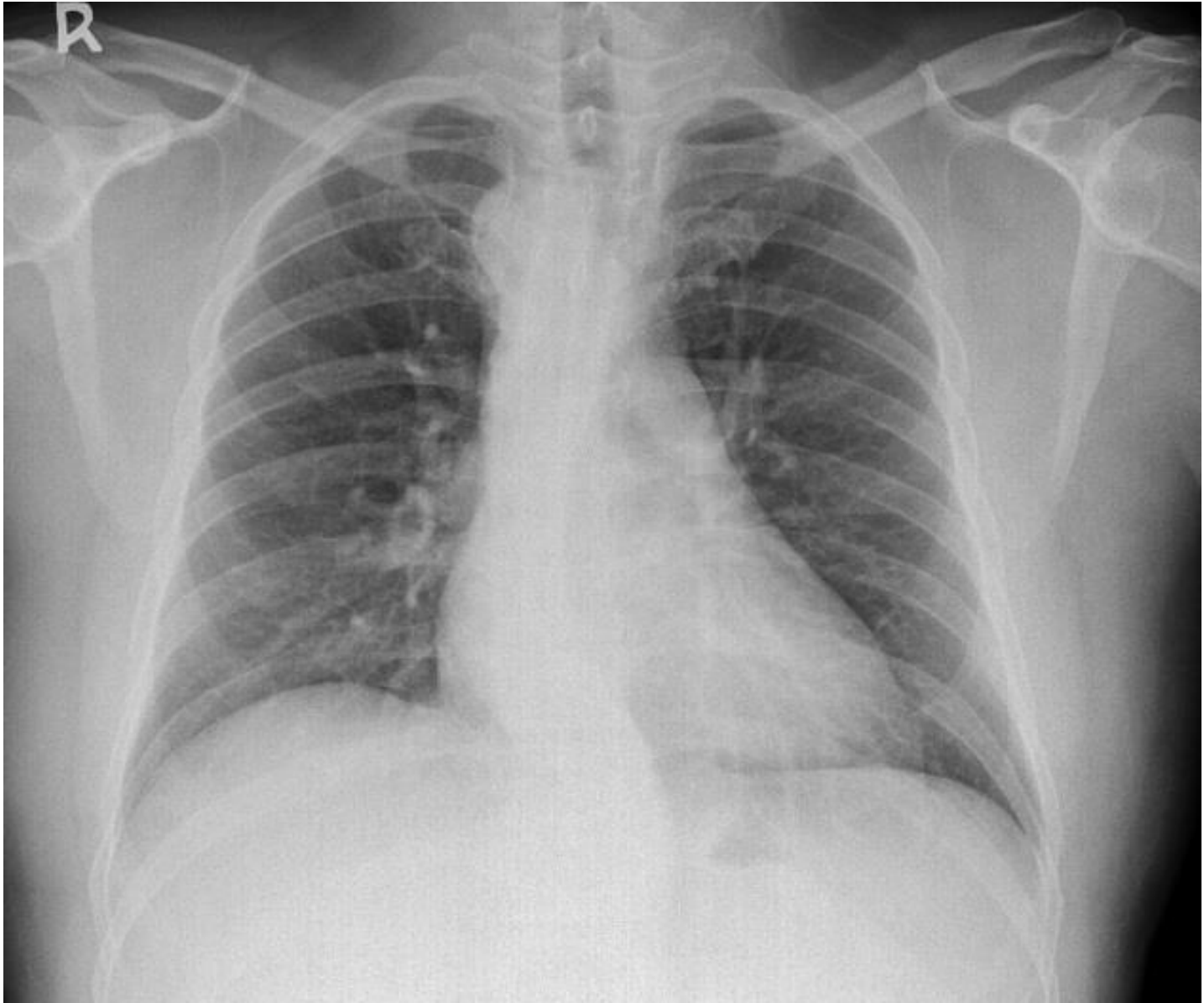


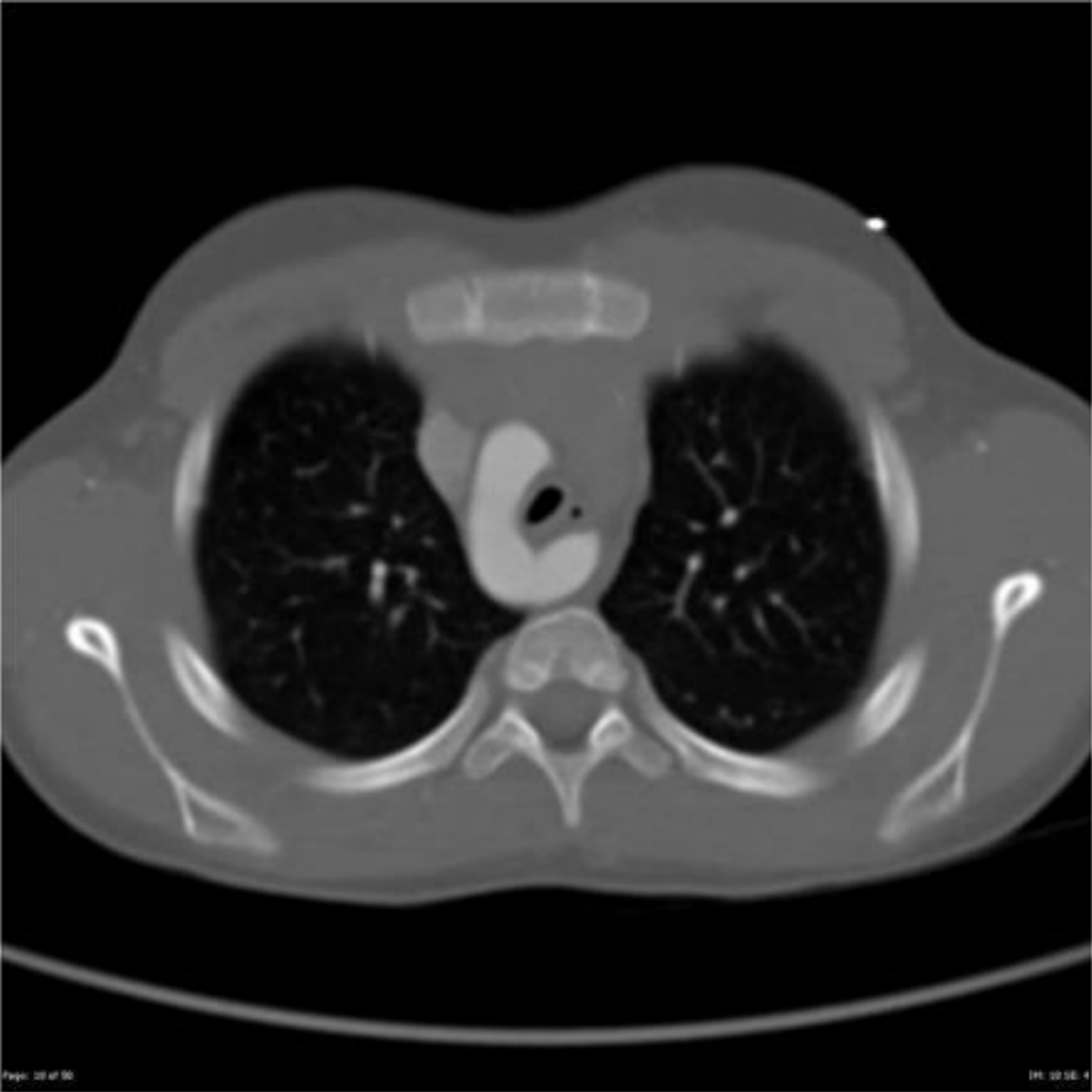


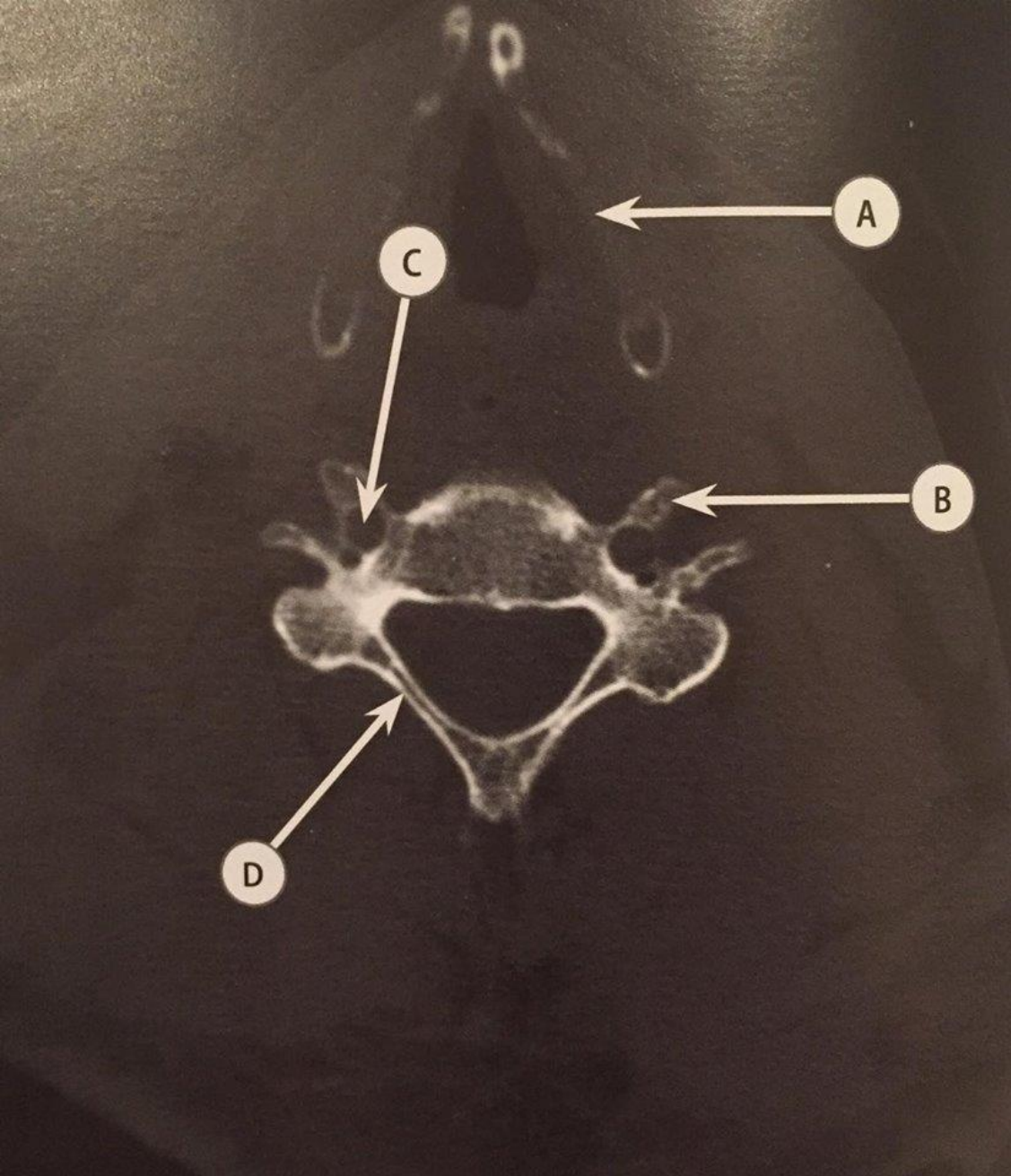


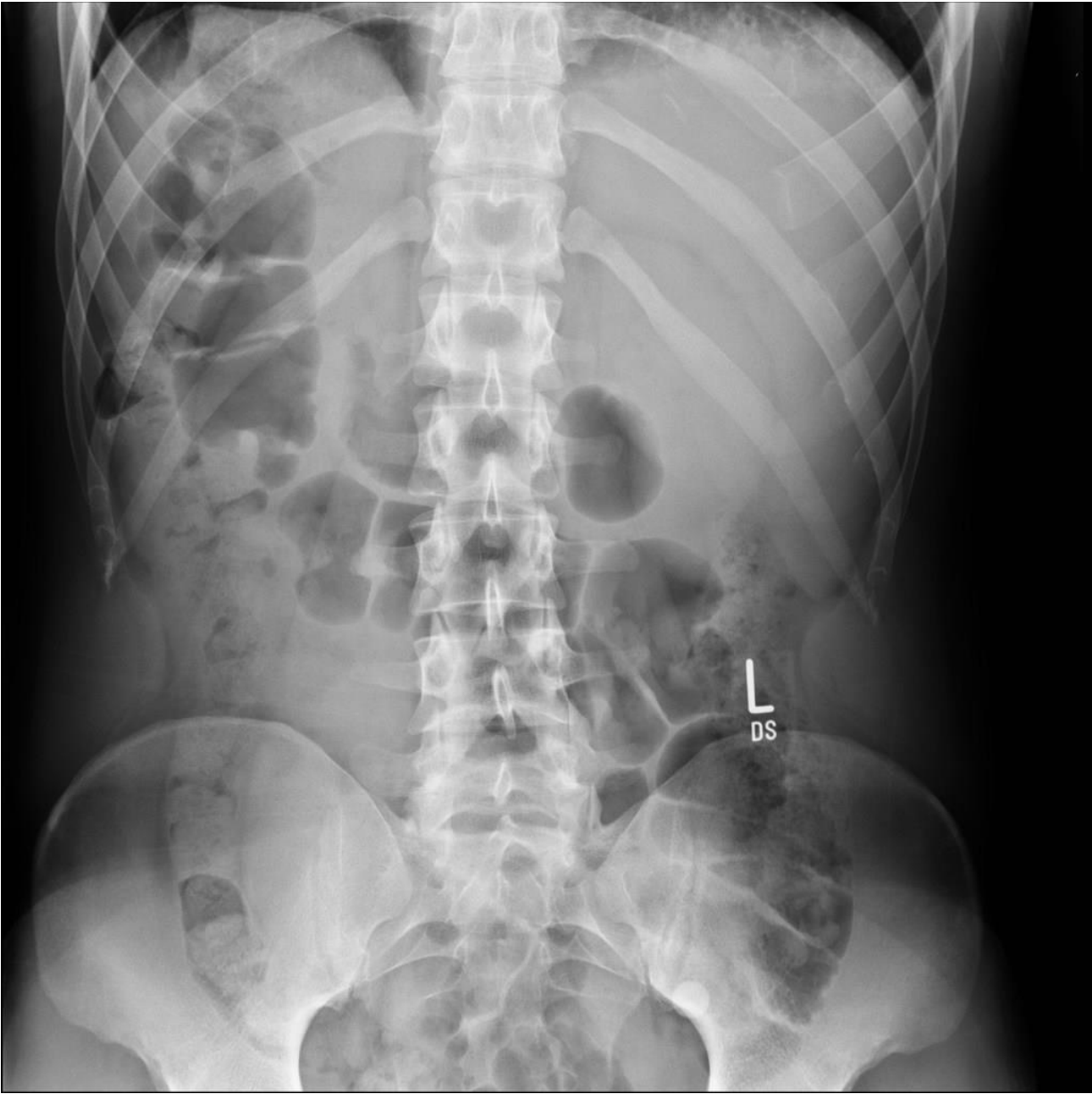


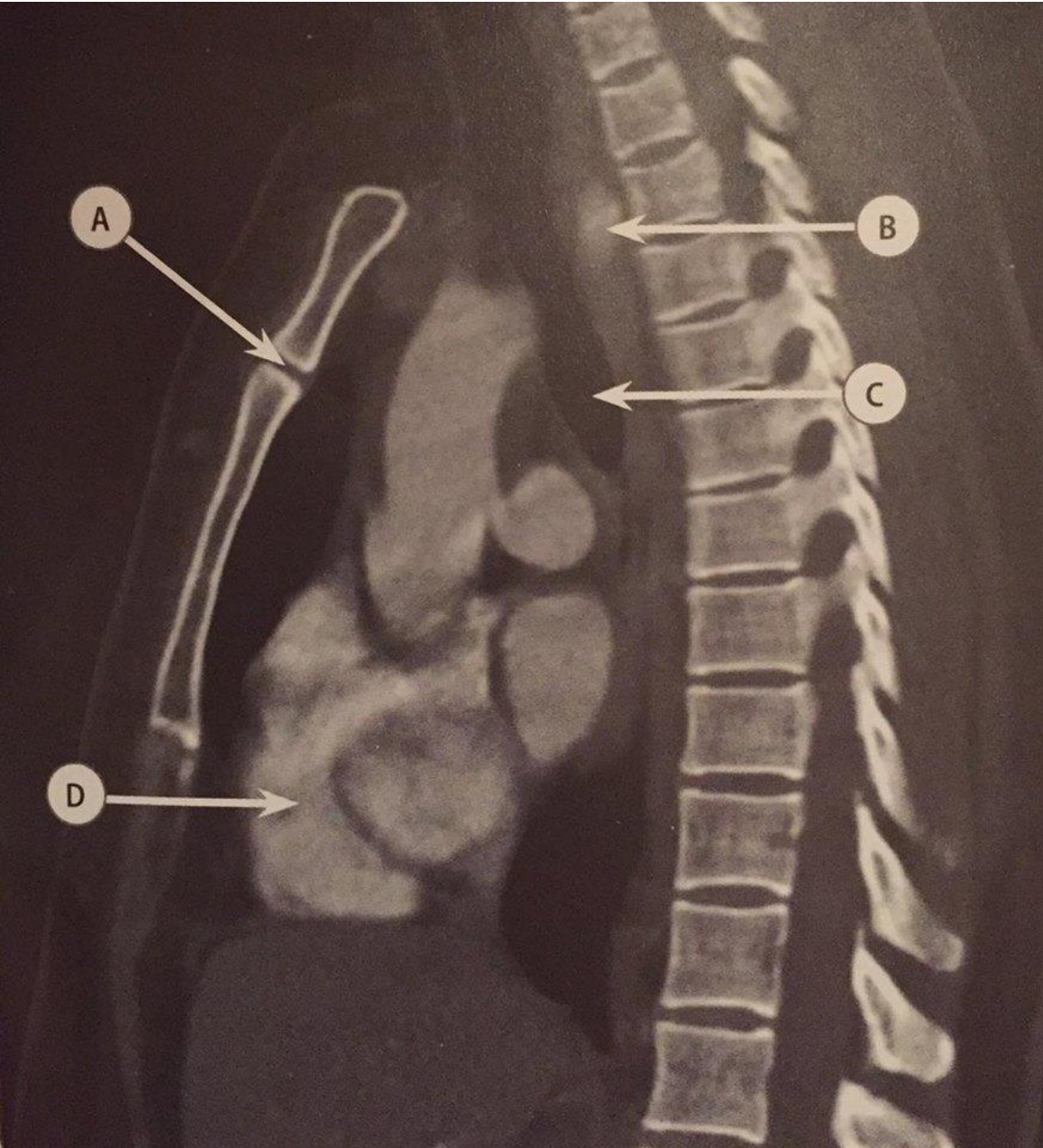




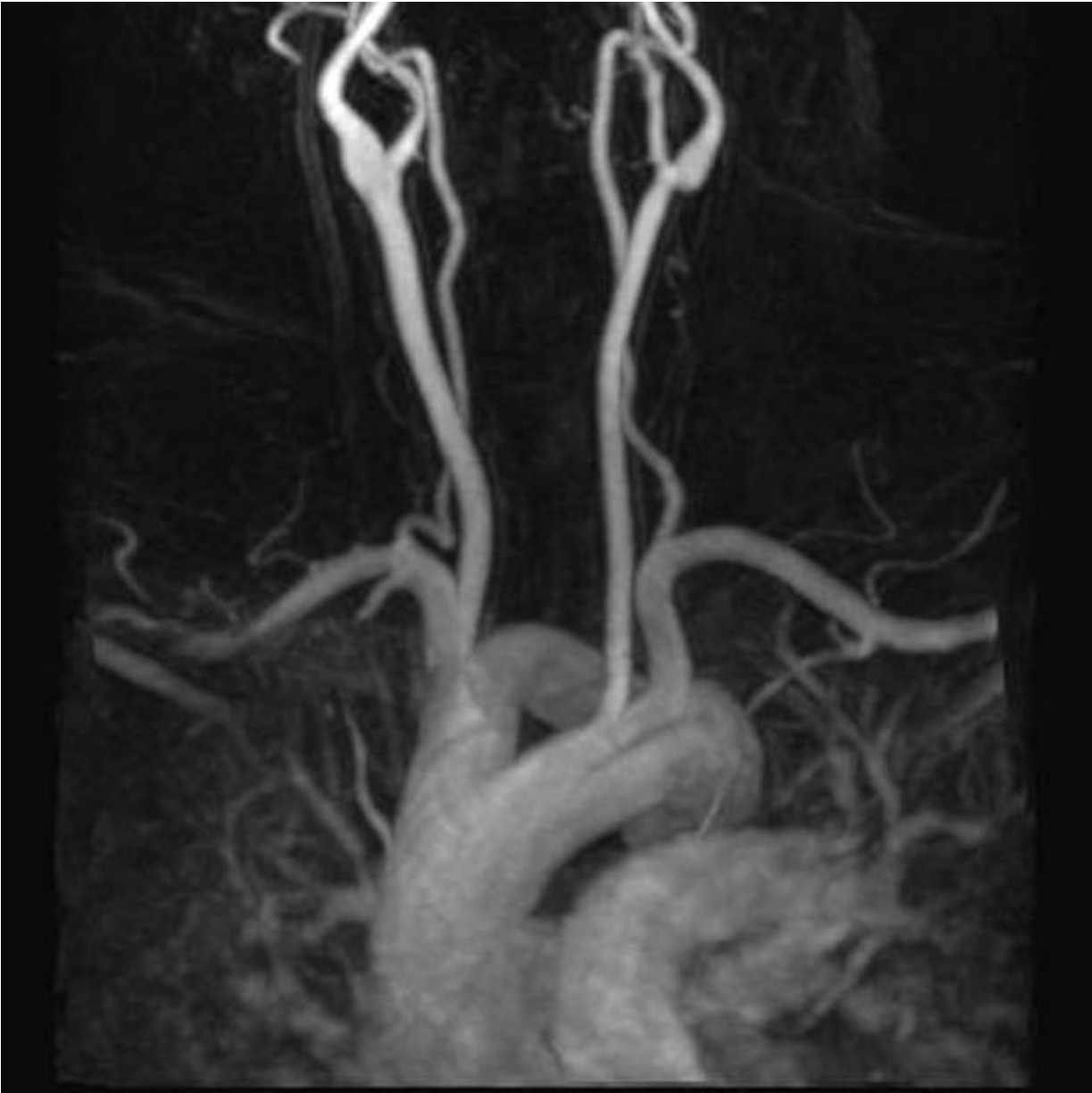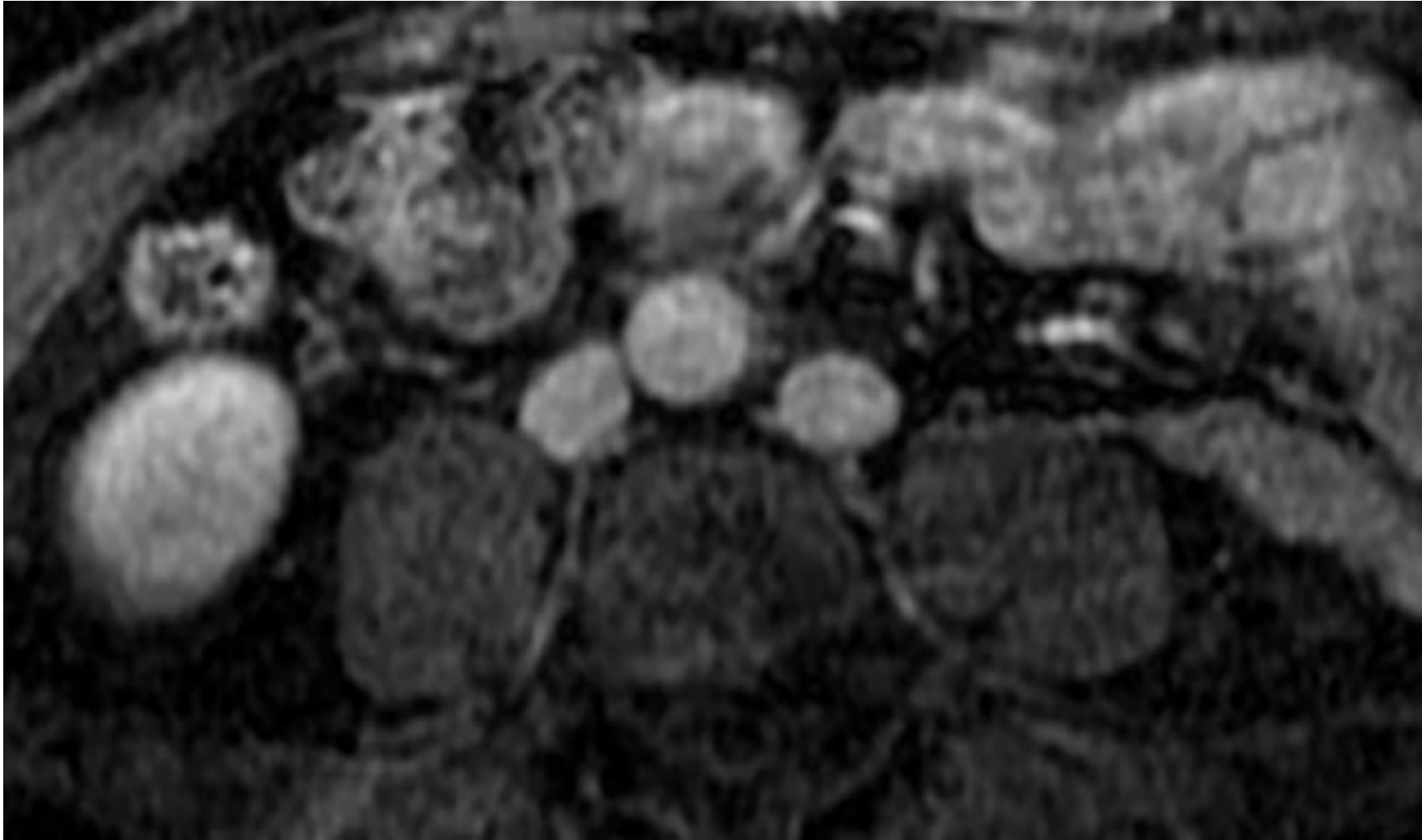


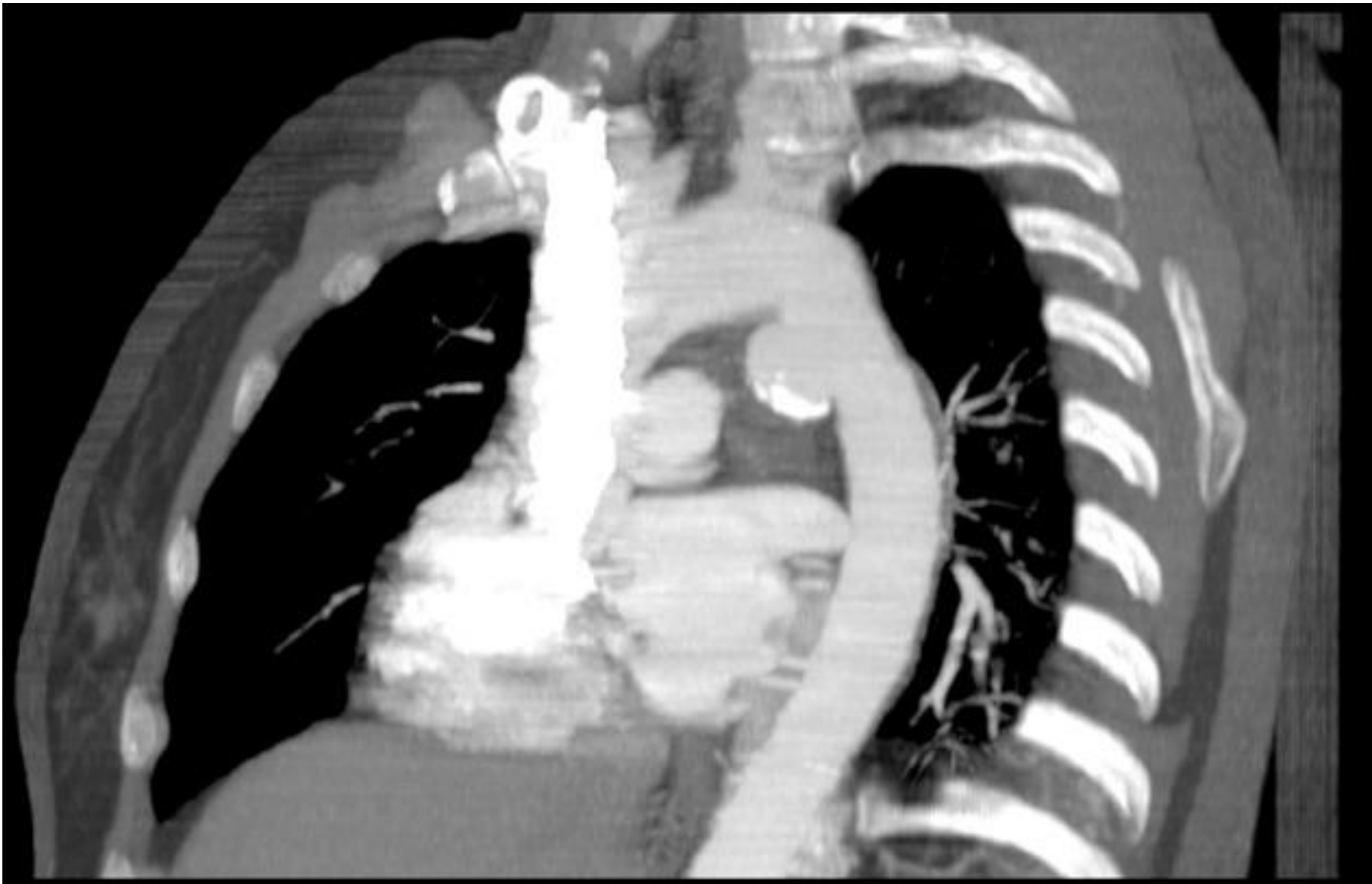






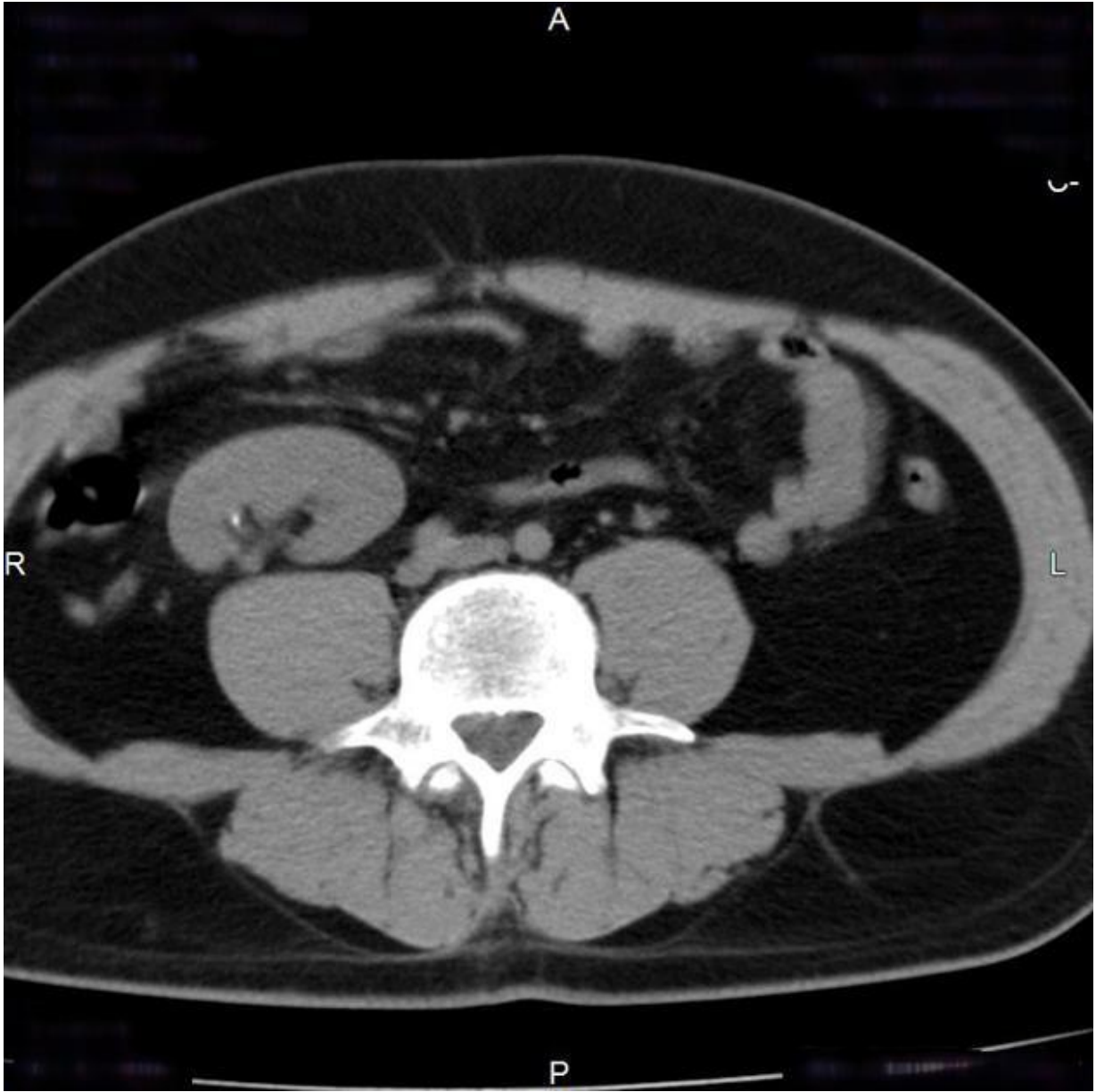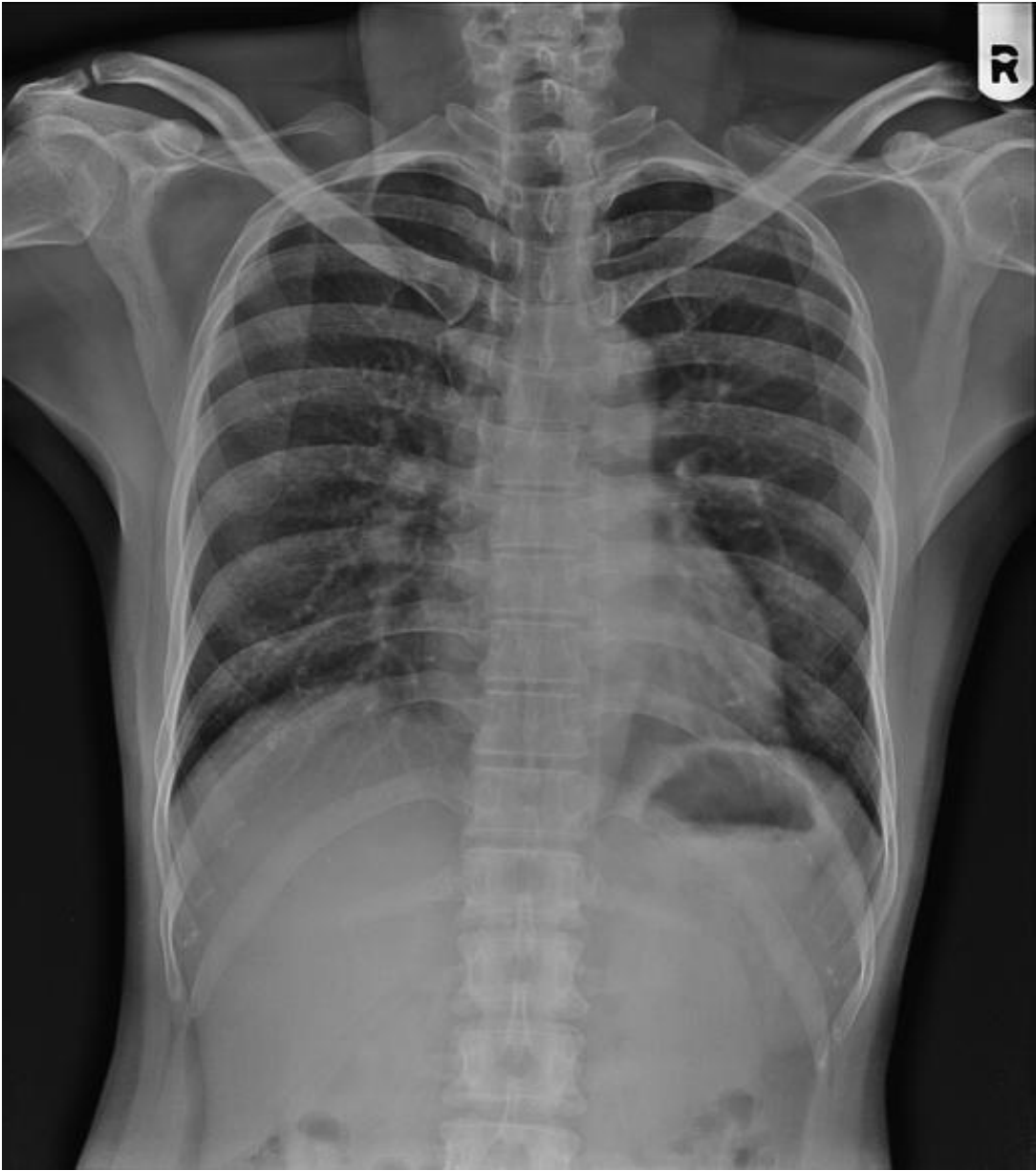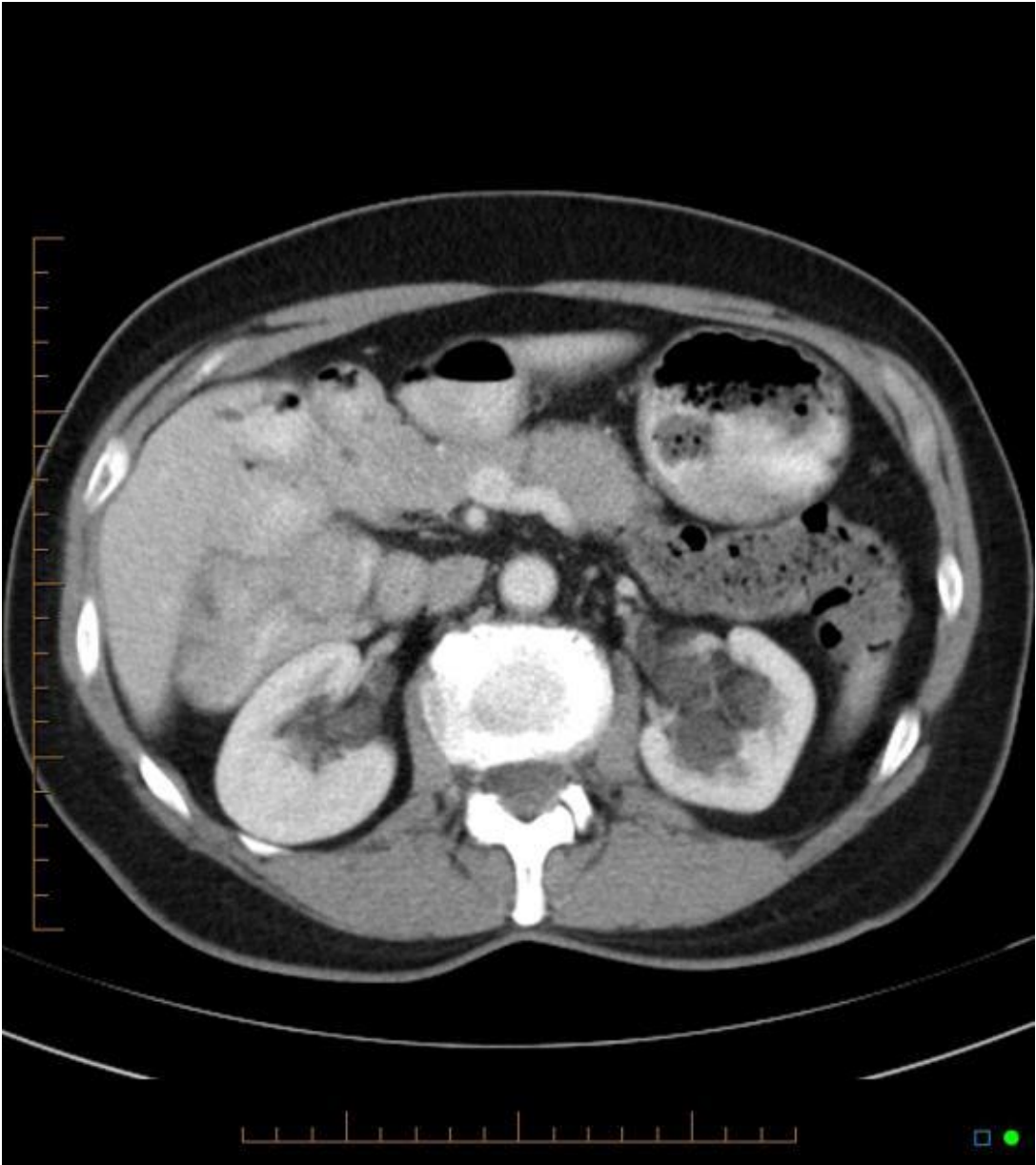


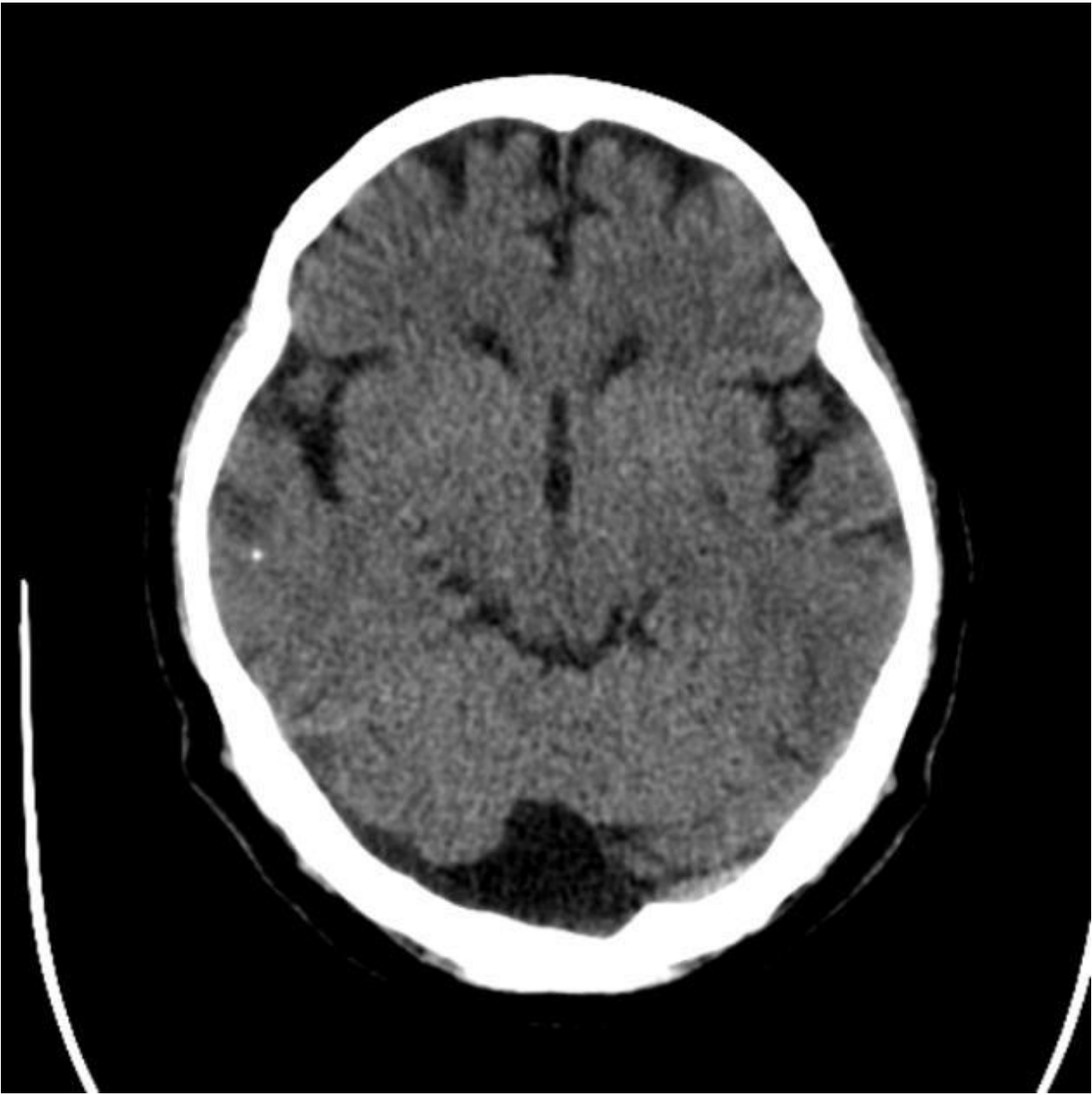


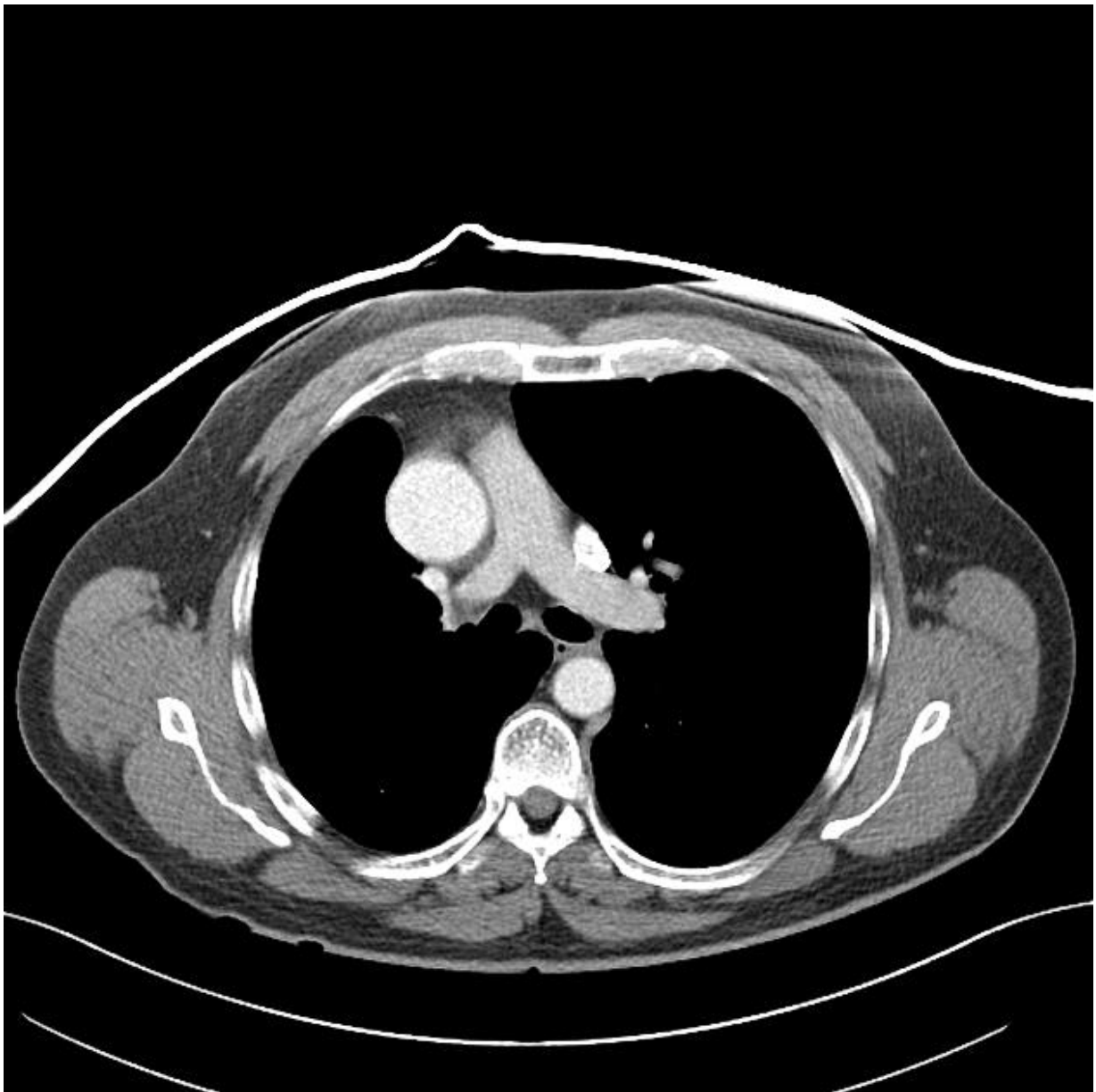


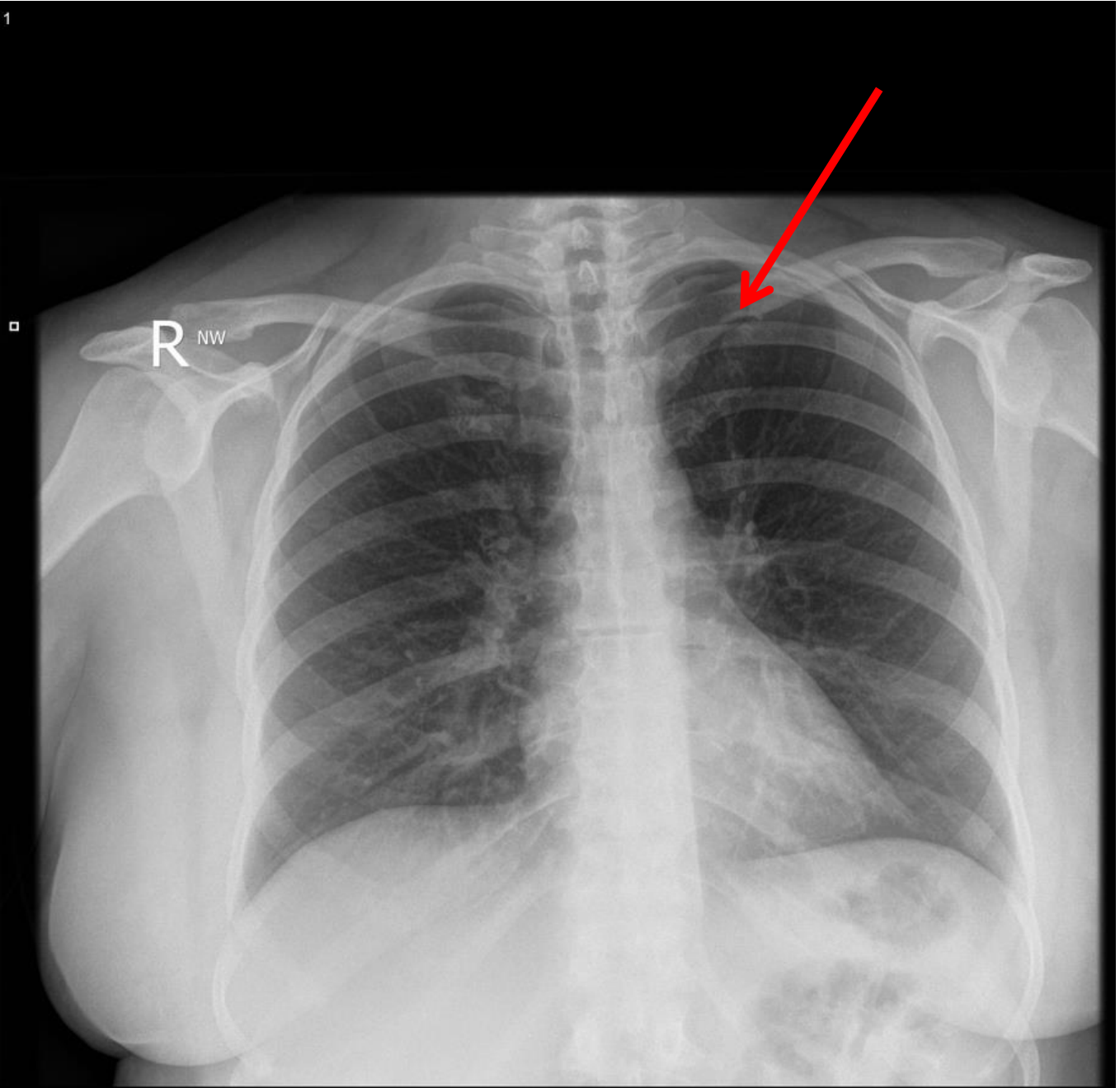


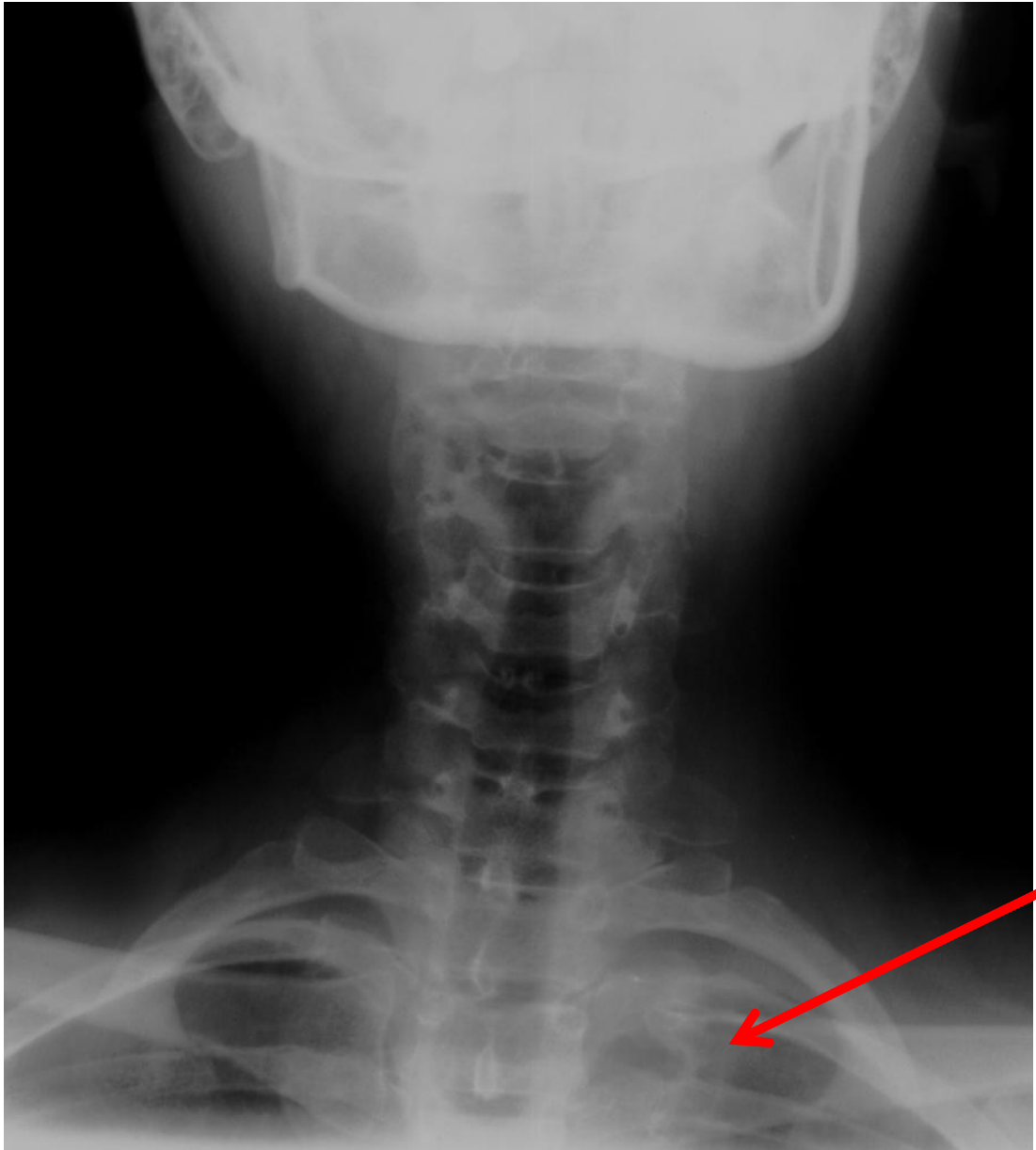


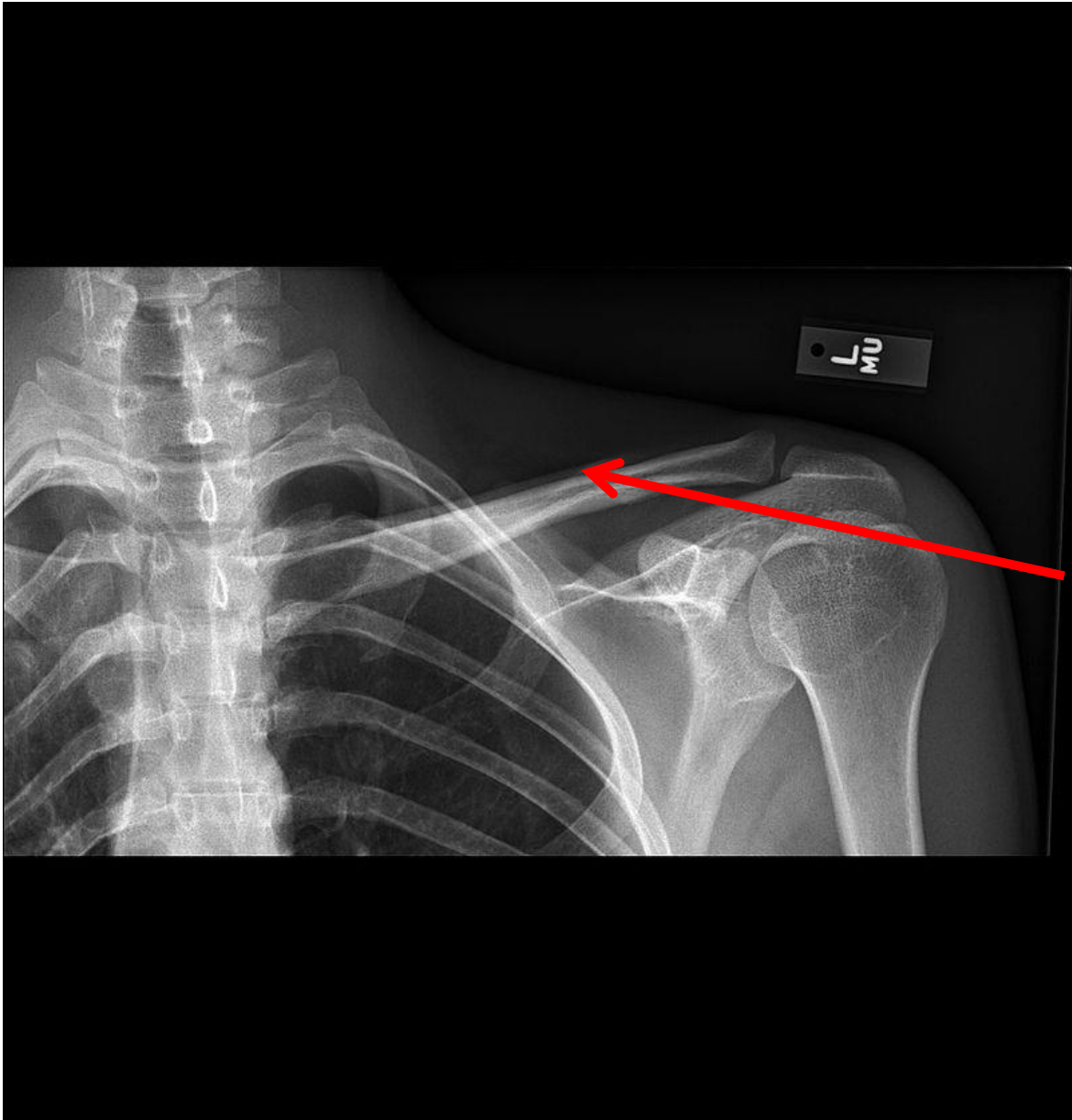






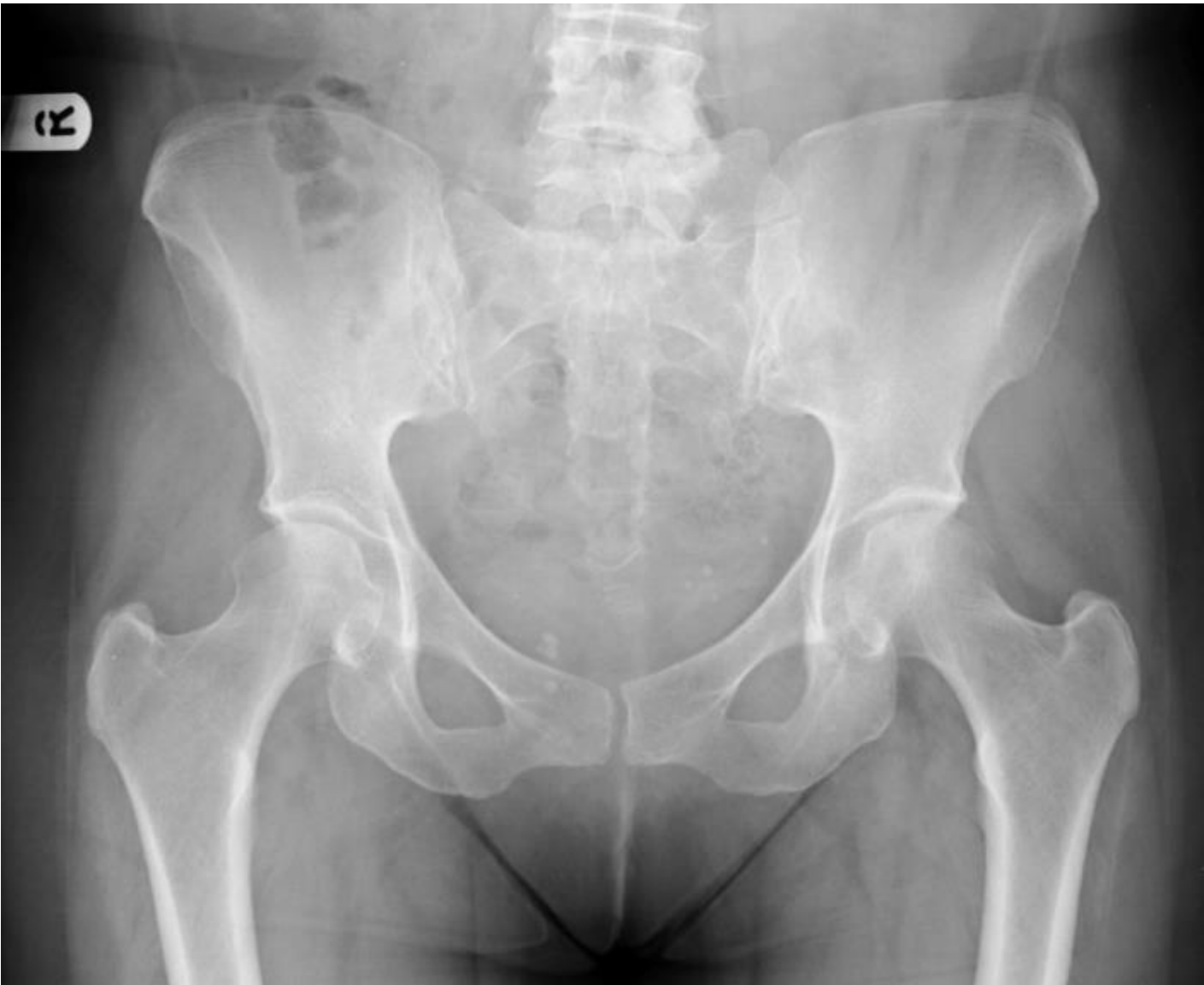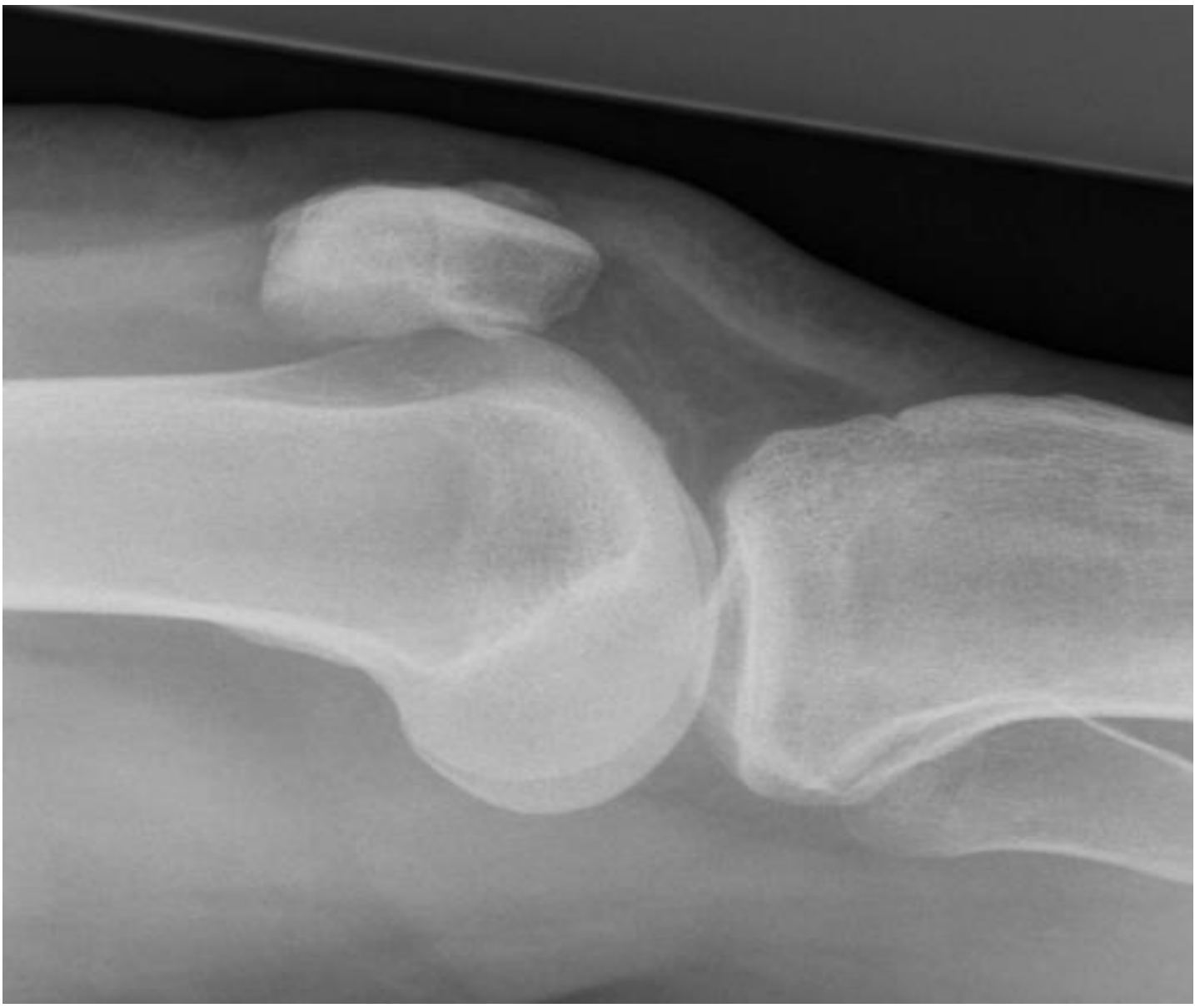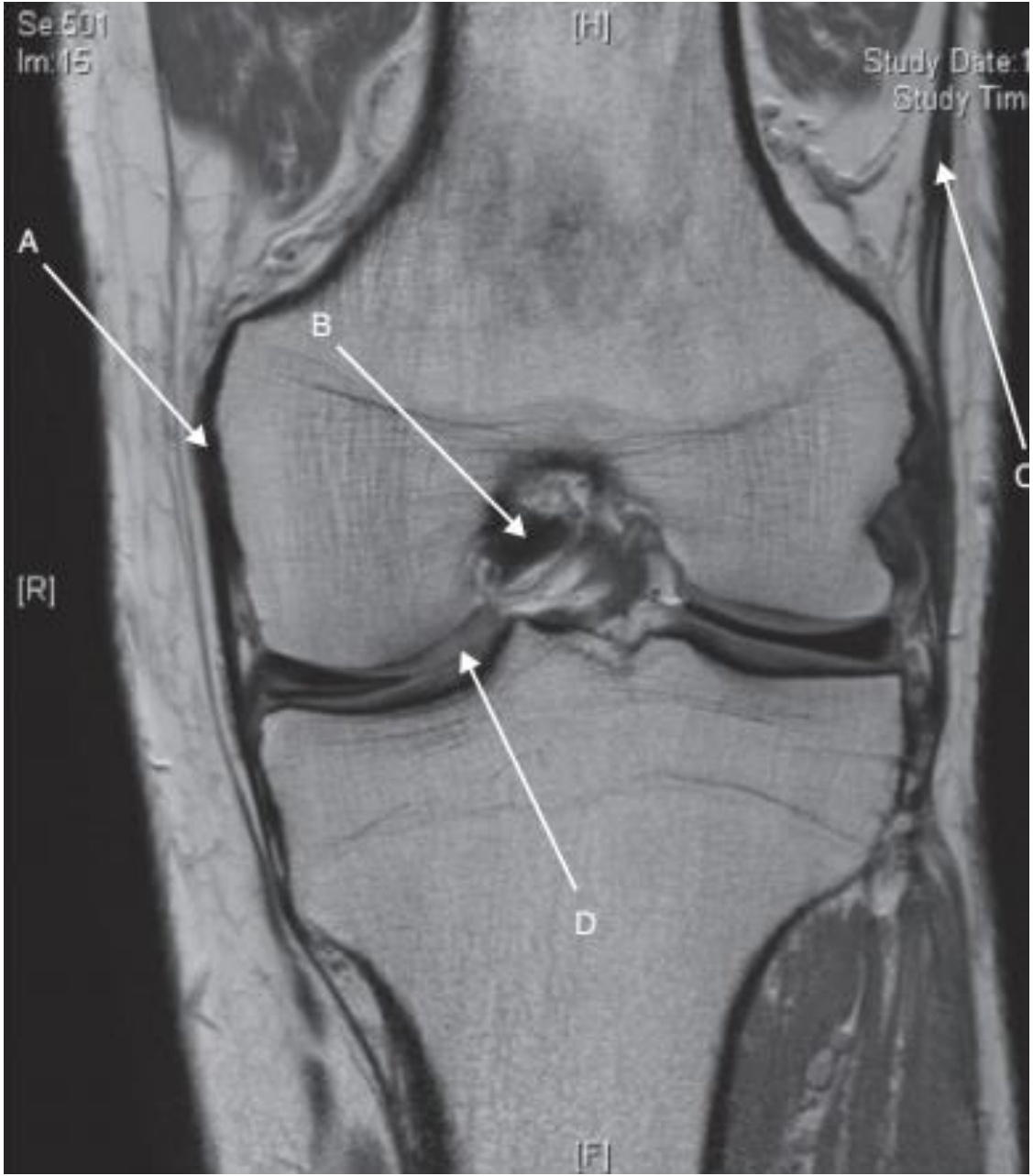








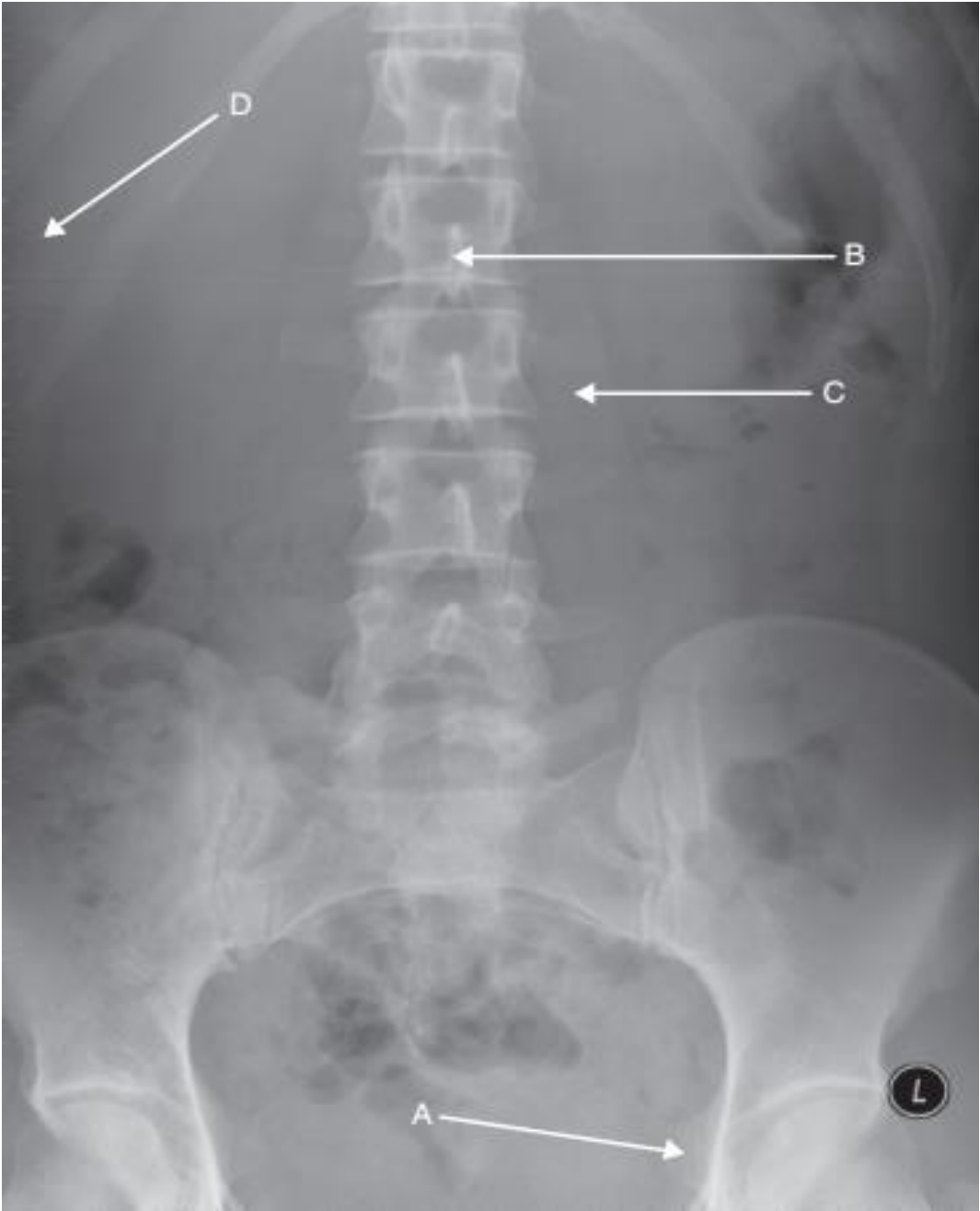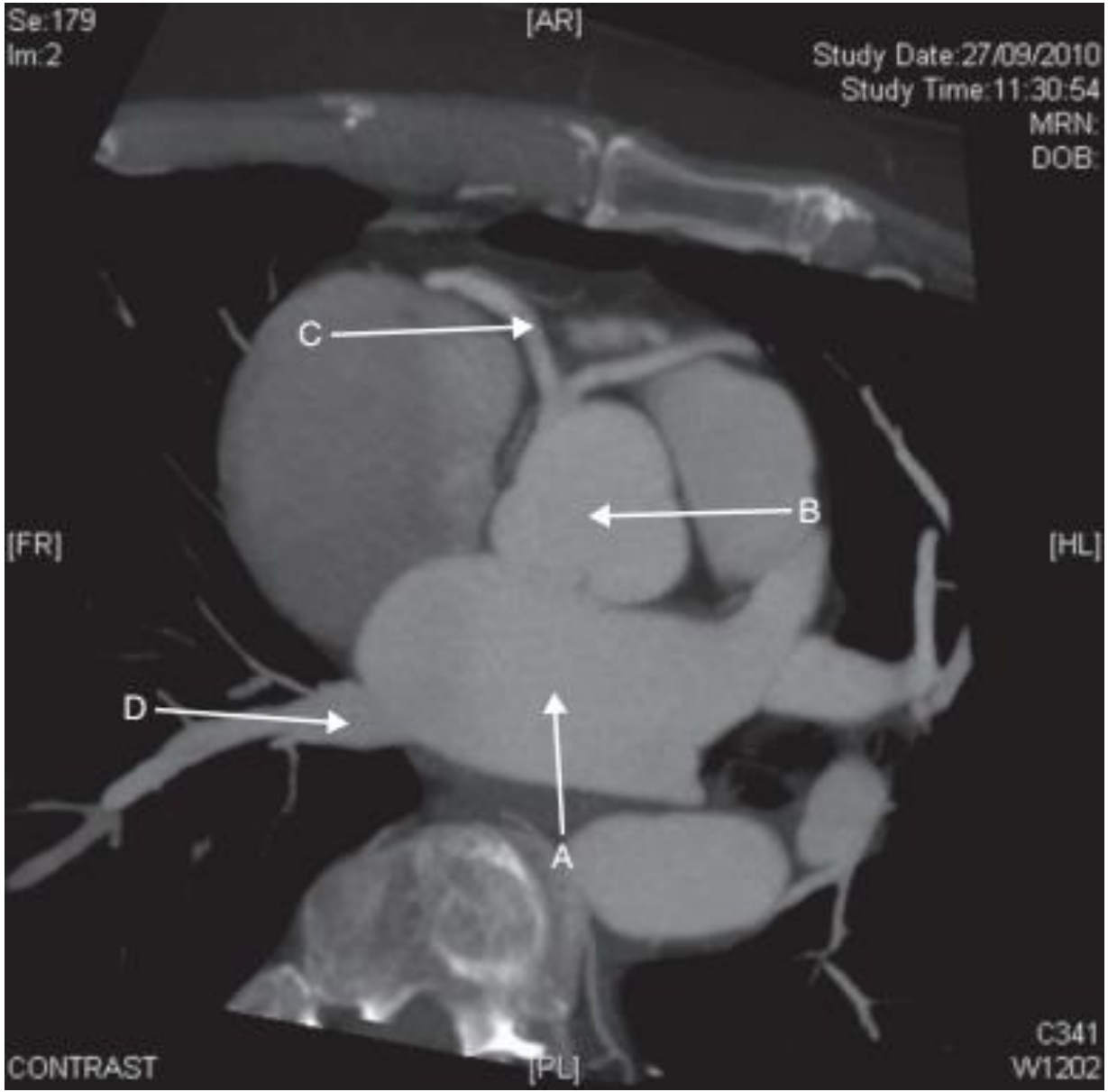




Name the normal variant

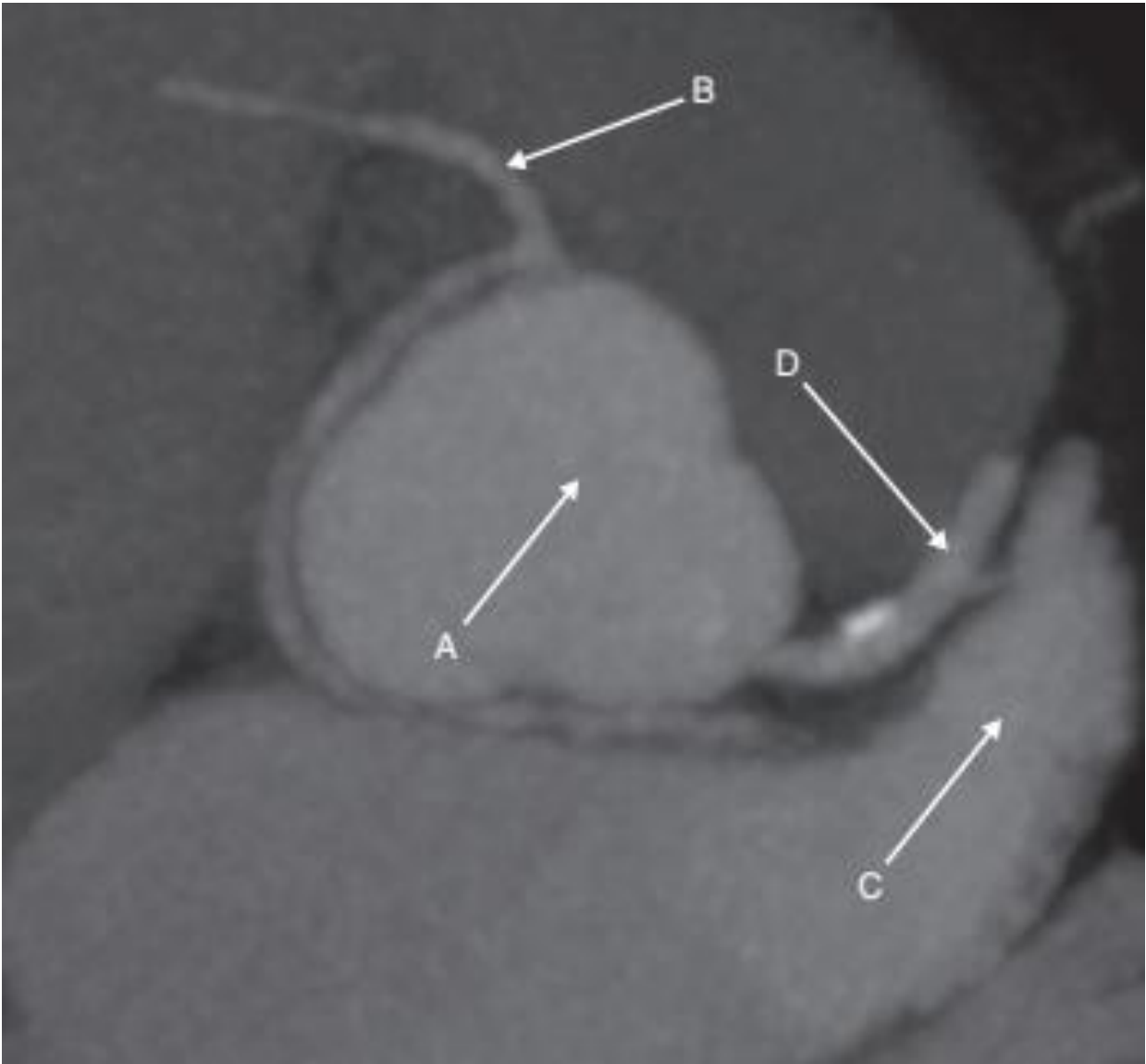
Name the normal variant

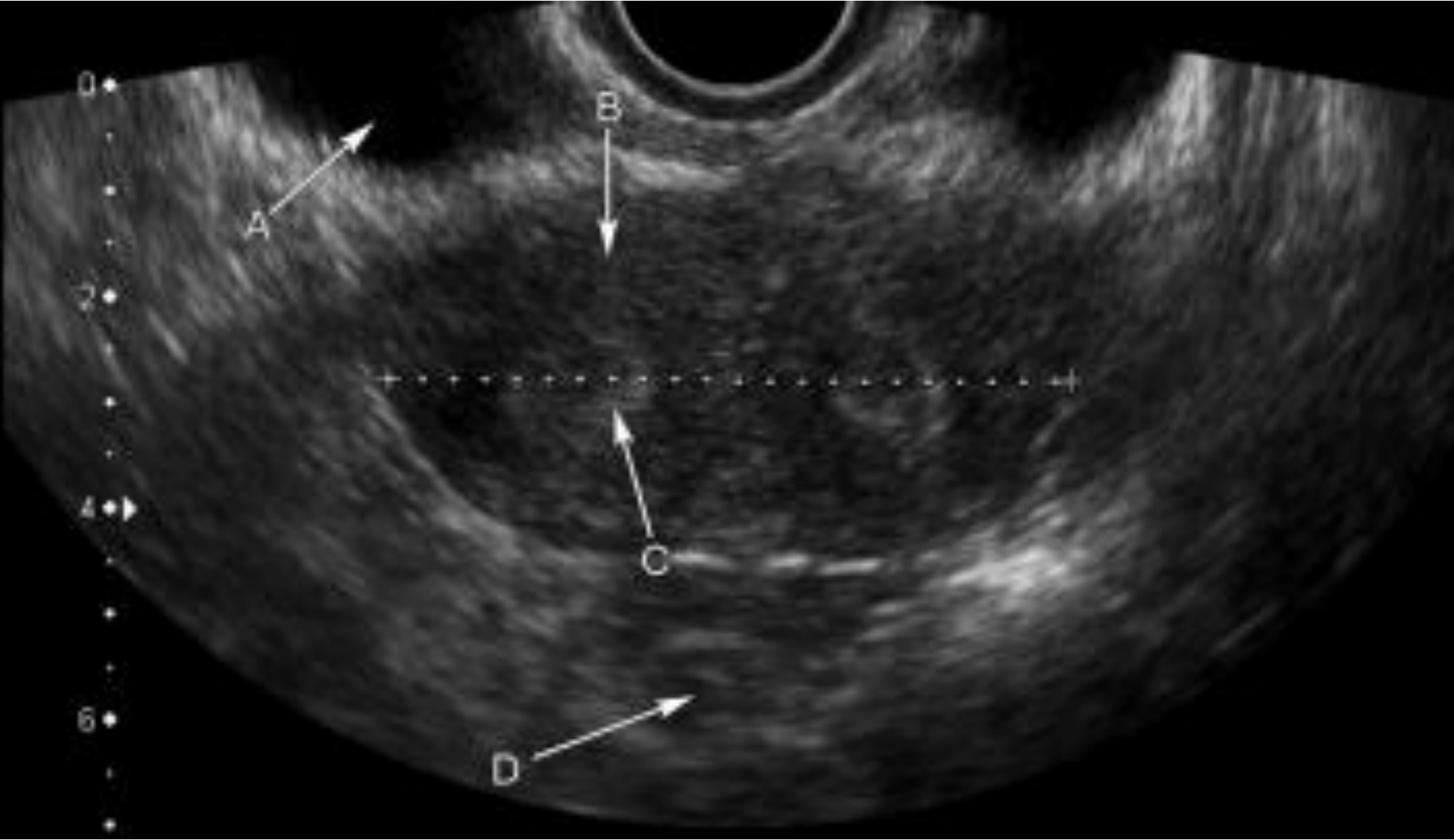


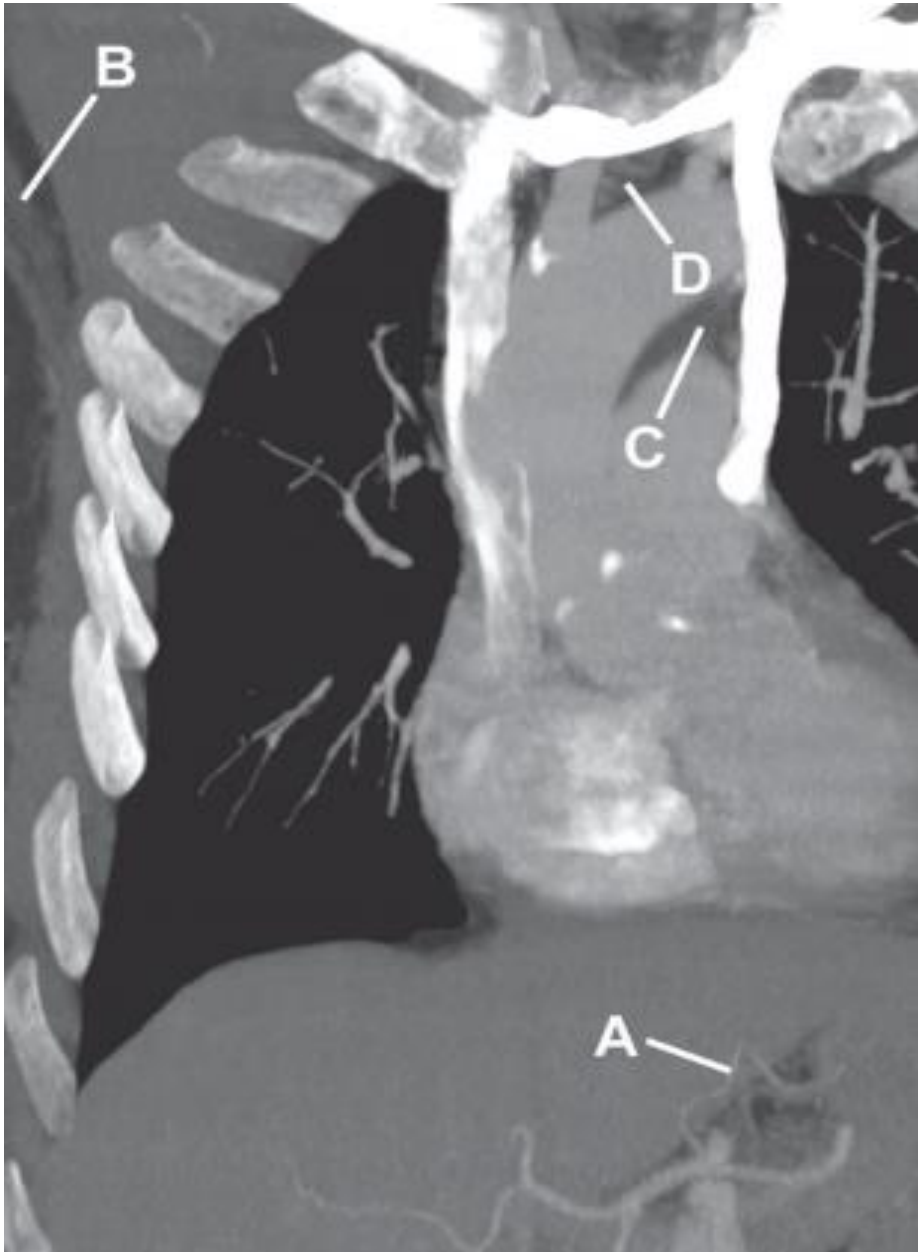


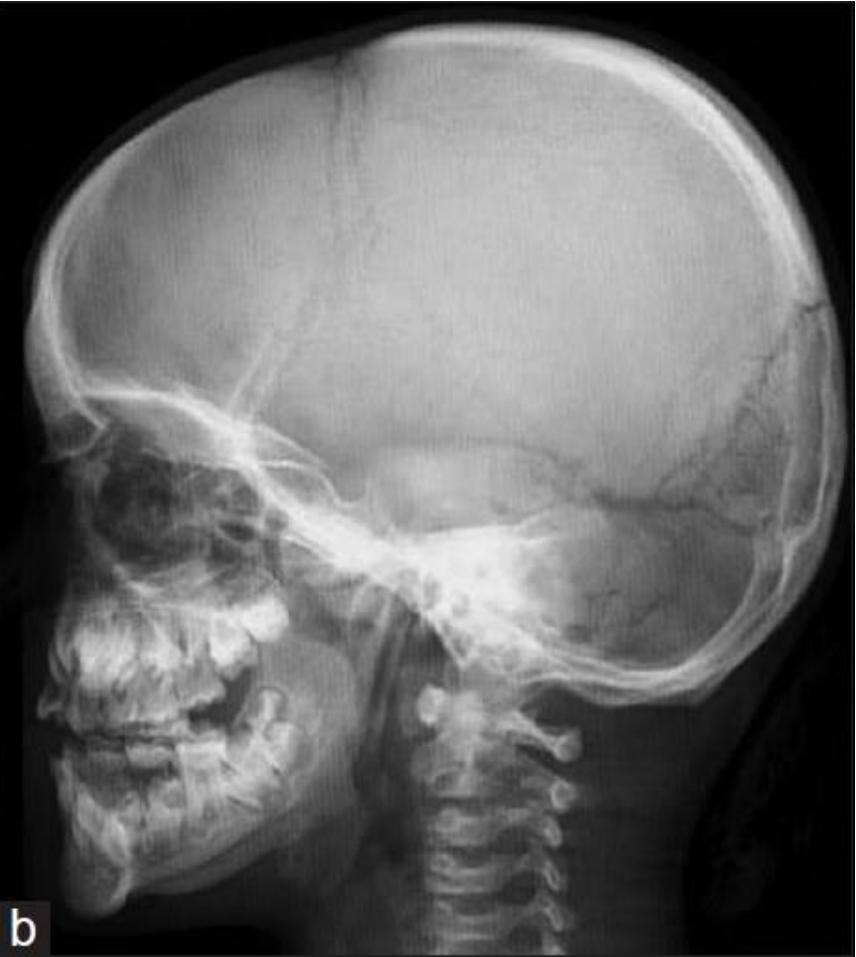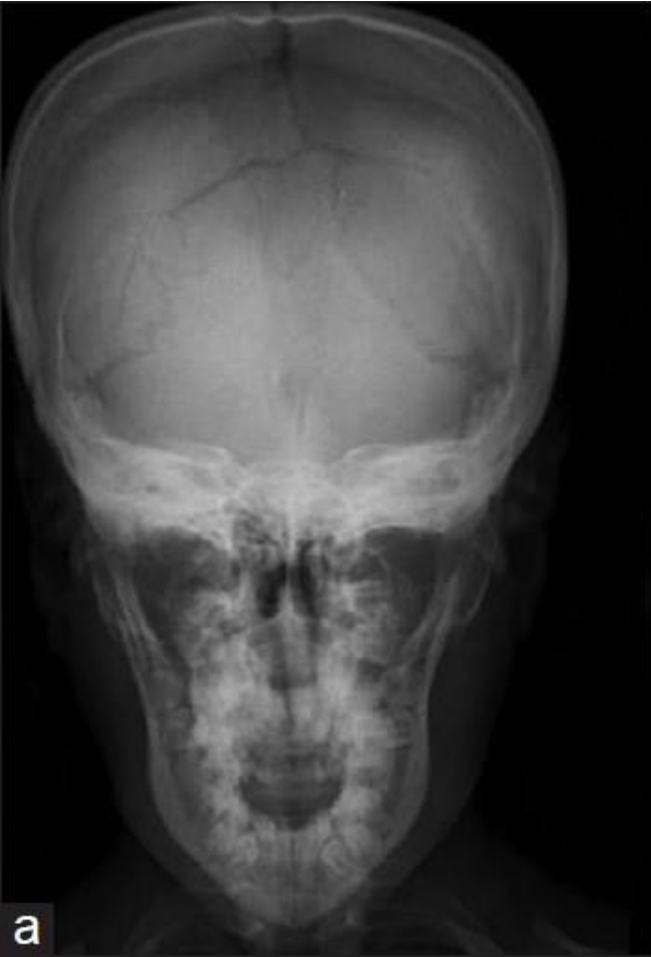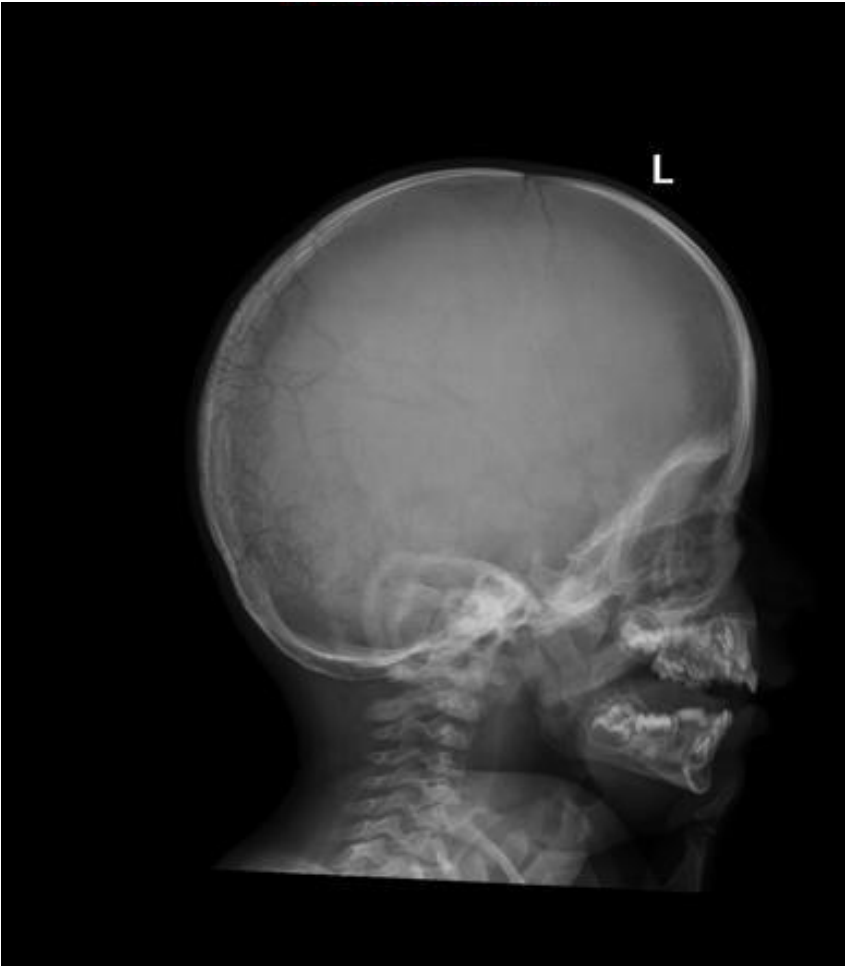Name the normal variant

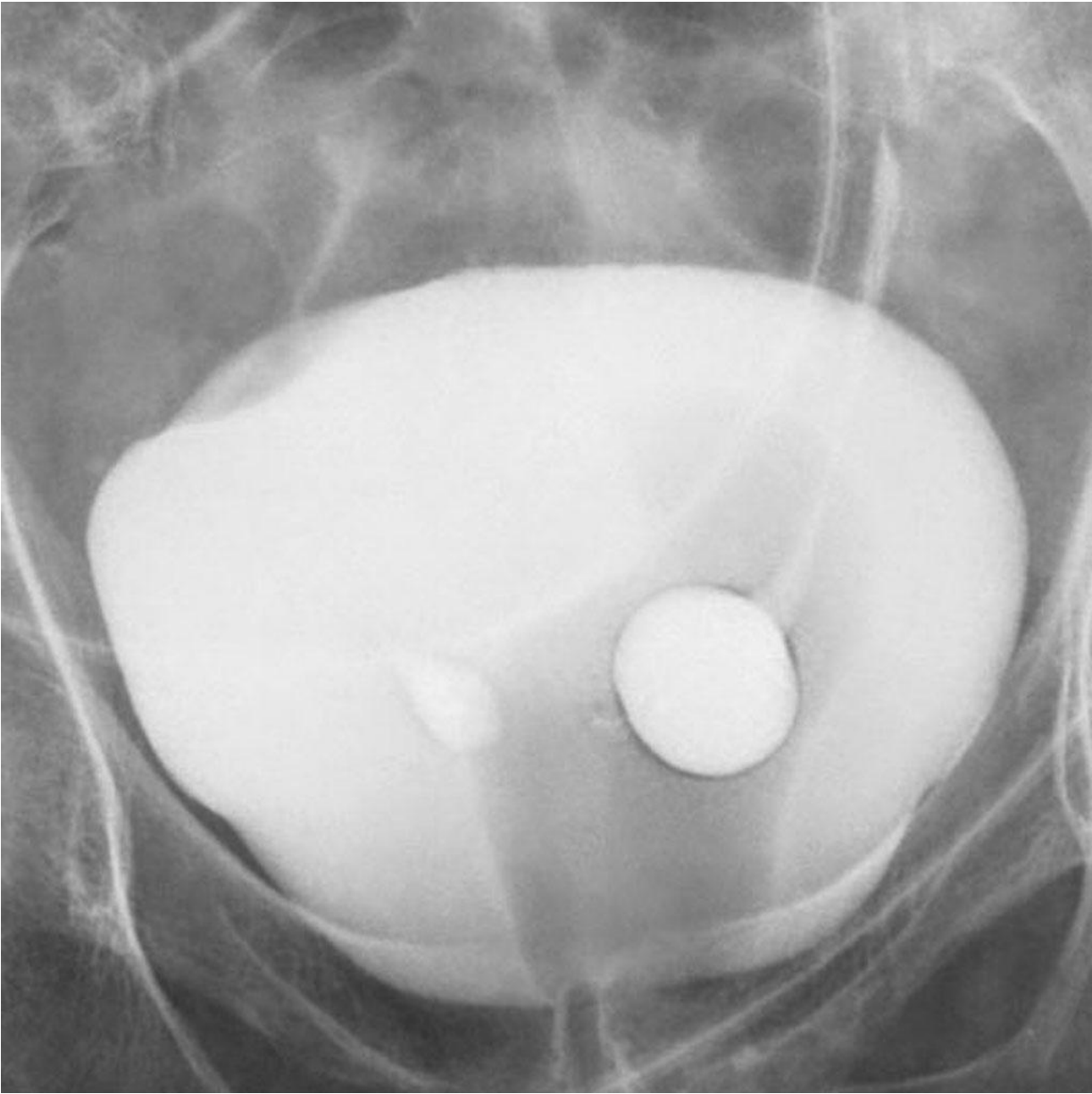Name the normal variant











Acknowledgements

These examples have been compiled from the different resources listed below and other clinical cases...

